

COMPARATIVE STUDY OF PATHOGENICITY BETWEEN *ASPERGILLUS FUMIGATUS* AND *PENICILLIUM CHRYSOGENUM* IN MICE

S. N. Yassein

Assist. Prof.

Dept. of Microb., Coll. of Vet. Med. / University of Baghdad- Iraq.

Shaimaa_nabhan@yahoo.com

ABSTRACT

This study was conducted to compare between two types of opportunistic fungi (*Aspergillus fumigatus* and *Penicillium chrysogenum*) in concerning their pathogenicity after intraperitoneal inoculation of mice. A total of twenty four male albino mice were used in this study which divided equally into 3 groups, The first and second groups were inoculated with 0.2ml of 1×10^7 spores/ml of *A. fumigatus* and *P. chrysogenum* intraperitoneally respectively, while the third group was inoculated with normal saline which served as control group. All animals were monitored for 2 weeks after infection. The blood samples were collected by heart puncture after 18 days post infection to isolate of serum that used for biochemical analysis of liver and kidney functions. After that, all animals were sacrificed. Some internal organs of infected groups (liver, kidney, intestine, heart, spleen and lung) were taken to study the histopathological changes. It was found that there was severe histopathological changes in studied organs of infected mice particularly liver, kidney, spleen and intestine which corresponding with significant variation ($p < 0.01$) in enzyme activities of liver and kidney like (Alanine Aminotransferase (ALT), Urea and Creatinine). Also, It was found that *P. chrysogenum* had more impact on these enzymes (15.65 ± 0.78 , 135.23 ± 8.75 and 0.928 ± 0.02 respectively) than *A. fumigatus* (21.70 ± 1.04 , 57.91 ± 5.99 and 0.587 ± 0.03 respectively). Therefore, the present study indicated that fungi present in the environment can induce severe inflammation reach to tissue damage in most vital internal organs So, further studies should be performed to determine the specific virulence factors and active components, which are responsible for pathogenesis of *A. fumigatus* and *P. chrysogenum* in spite of the fact that *P. chrysogenum* can produce antibiotic.

Keywords:-Opportunistic fungi, Saprophytic fungi, ALT, Creatinine.

ياسين

مجلة العلوم الزراعية العراقية -2020: 51(عدد خاص):168-175

دراسة مقارنة بين امراضية فطر *Aspergillus fumigatus* و *Penicillium chrysogenum* في الفئران

شيماء نيهان ياسين

استاذ مساعد

فرع الاحياء المجهرية/ كلية الطب البيطري/ جامعة بغداد/ العراق

المستخلص

اجريت هذه الدراسة للمقارنة بين امراضية نوعين من الفطريات الانتهازية *Aspergillus fumigatus* و *Penicillium chrysogenum* بعد حقنها في داخل الخلب للفئران. استخدمت في هذه الدراسة 24 فأراً ذكراً وقسمت بالتساوي الى 3 مجاميع. حقنت المجموعة الاولى والثانية ب 0,2 مل من العالق السبوري وبتكريز 1×10^7 بوغ/مل من فطر *A. fumigatus* و *P. chrysogenum* على التوالي بينما المجموعة الثالثة حقنت بالمحلول الملحي الفسلجي كمجموعة سيطرة. تمت متابعة الحيوانات لمدة اسبوعين وبعدها تم سحب الدم من القلب وفصل المصل لغرض استخدامه للتحليل الكيميائي لوظائف الكبد والكلى. ثم قتلت الحيوانات واخذت بعض الاعضاء الداخلية مثل الكبد، الكلى، الامعاء، القلب، الطحال والرئة لغرض اجراء الفحص النسيجي. لوحظت هناك تغييرات نسيجية مرضية حادة في الاعضاء المأخوذة والتي تزامنت مع الاختلاف المعنوي ($p < 0.01$) لفعالية انزيمات الكبد والكلى المتمثلة ب (ALT, Urea and Creatinine). استنتجت هذه الدراسة ان بعض انواع الفطريات الموجودة في البيئة ممكن ان تؤدي الى حدوث التهابات حادة قد تصل الى تدمير النسيج لبعض الاعضاء الداخلية الحيوية. ولهذا يفضل اجراء دراسات اخرى لتحديد عوامل الضراوة والمركبات الفعالة المسؤولة عن امراضية *A. fumigatus* و *P. chrysogenum* بالرغم من كون الفطر الاخير منتج للمضاد الحيوي.

الكلمات المفتاحية: الفطريات الانتهازية، الفطريات الرمية، الكرياتينين، الرشاشيات الدخلاء.

INTRODUCTION

Aspergillosis is an umbrella term that contain wide range of diseases from localized to fatal disseminated infections in human and various types of animals. (24). *Aspergillus fumigatus* is the most common and life-threatening ubiquitous airborne opportunistic fungal pathogen, especially significant among immunocompromised hosts (15, 26). It is present in the environment, particularly in air, water, plants and soil (1, 20) When its conidia are inhaled, it can be responsible for wide range of distinct clinical entities (8). The ability of this species to cause different types of diseases is due to possess various virulence factors which help with fungal survival and persistence in the host resulting in tissue damage and disease (7). Otherwise, *Penicillium* is one of the largest and most important genera of fungi, more than 400 described species distributed worldwide (2,32). These fungi are broadly present in nature including air, soil, cereal grains, hay and other plant materials or foodstuff. Exposure to these fungi has been associated with a variety of adverse health outcomes including respiratory, hematological, immunological, and neurological system disorders and/or diseases (21). *Penicillium chrysogenum* is a filamentous fungus of major medical and historical importance (5). Many studies reported high percentage of respiratory problems, mammary gland infection and other diseases caused by *Penicillium* spp. (3, 6, 10) but there is no or rare information about the effect *Penicillium chrysogenum* on the internal organs. So, the main objective of this study was to determine the similarity or different

MATERIALS AND METHODS

Source of fungal isolates

A. fumigatus and *P. chrysogenum* were isolated from nasal swabs of sheep suffering from recurrent pulmonary infections in the winter of 2017. These isolates were cultured on Sabouraud dextrose Agar (Himedia -India) and incubated at 28±2°C for 4-7 days then diagnosed macroscopically and microscopically according to Washinton et al., (29). Spore suspension was prepared for both fungi according to Van der Velden et al., (28)

and adjusted to 1x 10⁷ spores/ml according to Mirkov et al., (17).

Experimental design

A total of twenty four male albino mice with 10-12 weeks in age and weight 20-28gm were used in this study which divided equally into 3 groups (8 animal for each group) and kept in large plastic cages for one week before beginning the experiment. The first group was inoculated with 0.2ml of 1x10⁷ spores/ml of *A. fumigatus* intraperitoneally, the second group was inoculated with the same dose as well as the same route with *P. chrysogenum* according to Odeh and Adekunle (21), while the third group was inoculated with normal saline which served as control group. All animals were monitored for 2 weeks after infection. The blood samples were collected by heart puncture after 18 days post infection to obtain of serum that used for biochemical analysis.

Histopathological examination

All animals were sacrificed and one cm³ of some internal organs of infected groups like (live, kidney, intestine, heart, spleen and lung) were taken and fixed in 10% natural formalin buffer solution which replaced after 24 hrs. till the preparation of histological section. Tissue were embedded in paraffin and several tissue sections were prepared for histopathological sections were stained with Hematoxylin – Eosin stain (H&E) according to Bancroft and Stevens (4).

Statistical analysis

The statistical analysis system- SAS (22) program was used to detect the effect of difference groups in study parameters. One way analysis of variance (ANOVA) was used to compare between means using Least Significant Difference-LSD in this study.

RESULTS AND DISCUSSION

A. fumigatus is considered one of the most common saprophytic fungi in the environment, and in the same time, It is opportunistic pathogen can cause different types of mycosis ranging from allergy to invasive and fatal disseminated Aspergillosis through its presence as ubiquitous airborne conidia (7, 15, 16), So, there are many studies were performed to determine effect of *A. fumigatus* when inoculated intranasally into mice and conducted to that the normal host can be suffering from systemic Aspergillosis (13, 14,

25). But the present study focused on the efficacy this type of fungi on the some internal organs when administered intraperitoneally into mice as a sequel to disseminated Aspergillosis. Therefore, the histopathological lesions of the animals infected intraperitoneally with *A. fumigatus* for two weeks showed increase thickness of alveolar septa due to infiltration of mononuclear cell (MNC) and presence of hemosiderin pigment in the interstitial tissue of lung (Fig.1), and infiltration of mononuclear cell (MNC) in lamina propria of intestine with hyperplasia of epithelial cells as in (Fig.2). Kidney sections showed infiltration of inflammatory cells like mononuclear cell (MNC) in interstitial tissue and in glomeruli with dilation of bowman's space (Fig.3) Liver sections revealed aggregation of mononuclear cell (MNC) as granuloma in hepatic interstitial and necrosis of hepatocytes (Fig.4). While other section showed apoptotic cell and infiltration of inflammatory cells in dilated sinusoids as in Fig. 5. Also, the spleen sections revealed infiltration of inflammatory cells like mononuclear cell (MNC) and presence of hemosiderin pigment (Fig. 6). Heart sections showed infiltration of mononuclear cell (MNC) between dilated myocardial fibers (Fig.7).

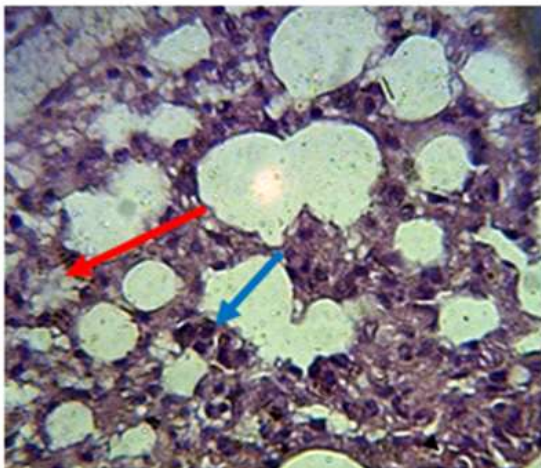


Figure 1. Histopathological changes in lung of infected animal with *A. fumigatus* for two weeks shows increase thickness of alveolar septa with infiltration of mononuclear cells (MNC) (red arrow) and presence of hemosiderin pigment in the interstitial tissue of lung (blue arrow)(H&E stain, X400)

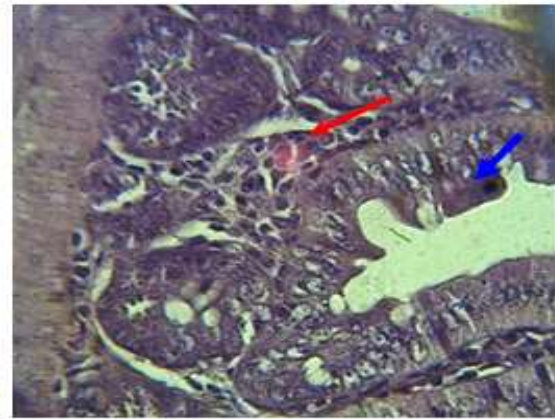


Figure 2. Histopathological lesions of intestine for two weeks of infection with *A. fumigatus* shows infiltration of inflammatory cells in lamina propria of villi (red arrow) and hyperplasia of epithelial cells (blue arrow) (H&E stain, X400)

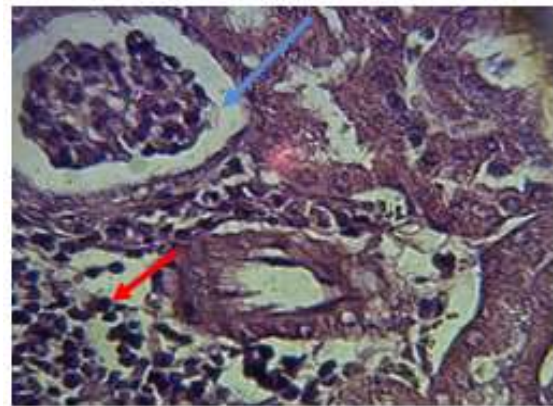


Figure 3. Histopathological changes in kidney of infected animal with *A. fumigatus* for two weeks shows infiltration of inflammatory cells like mononuclear cells (MNC) in interstitial tissue and in glomerular tufts (red arrow) with dilated of Bowman's space (blue arrow) (H&E stain, X400)

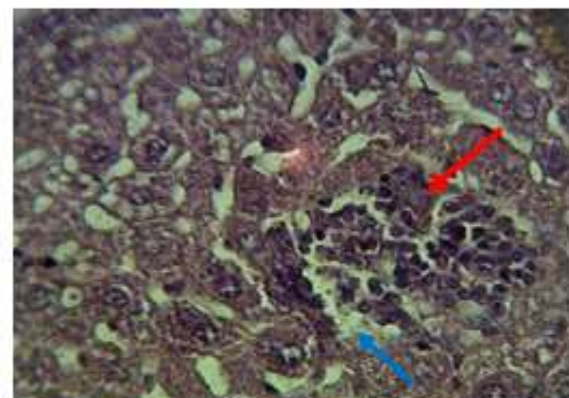


Figure 4. Histopathological changes in liver of infected animal with *A. fumigatus* for two weeks shows aggregation of mononuclear cells (MNC) as granuloma in hepatic interstitial (red arrow) and necrosis of hepatocytes (blue arrow) (H&E stain, X400)

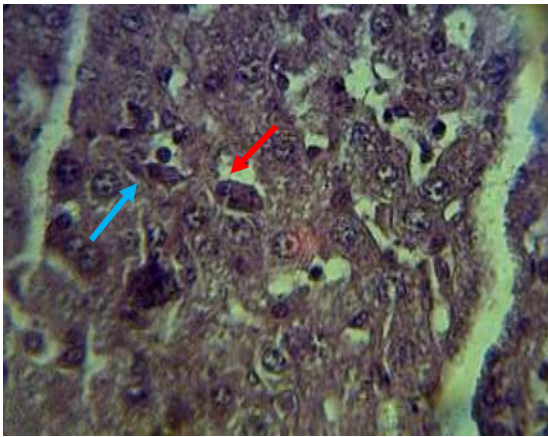


Figure 5. Histopathological changes in liver of infected animal with *A. fumigatus* for two weeks shows apoptotic cells (red arrow) and infiltration of inflammatory cells in dilated sinusoids (blue arrow) (H&E stain, X400)

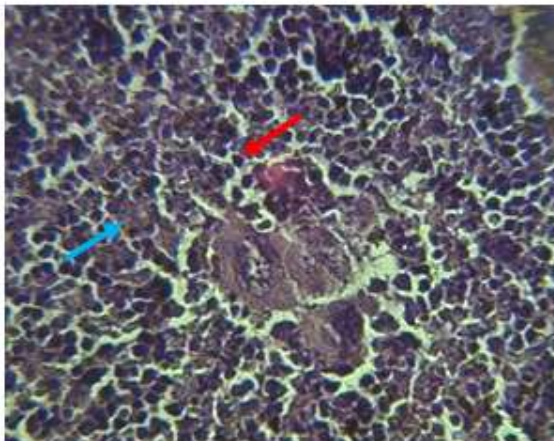


Figure 6. Histopathological changes in spleen of infected animal with *A. fumigatus* for two weeks shows infiltration of inflammatory cells like mononuclear cells (MNC) (red arrow) and presence of hemosiderin pigment (blue arrow) (H&E stain, X400)

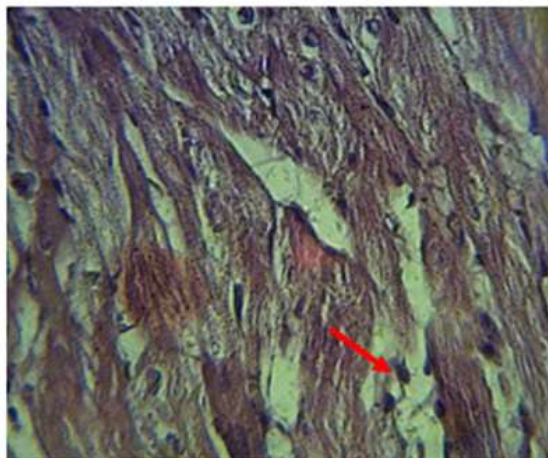


Figure 7. Histopathological changes in heart of infected animal with *A. fumigatus* for two weeks shows infiltration of inflammatory cells between dilated myocardial fibers (red arrow) (H&E stain, X400)

The liver of animals that infected with *P. chrysogenum* showed granulomatous aggregation of inflammatory cells around blood vessels and necrosis of hepatocytes as in (Fig. 8) and presence of apoptotic cells with arrangement of hepatocytes like cords (Fig. 9). The kidney revealed degeneration of epithelial cells of renal tubules, infiltration of inflammatory cells in glomerulus and renal parenchyma and atrophy of some glomeruli (Fig. 10). While the Intestine showed infiltration of inflammatory cells in mucosa and submucosa and hyperatrophy of goblet cells as in (Fig. 11). Heart sections of infected animal with *P. chrysogenum* for two weeks revealed infiltration of inflammatory cells between myocardial fibers which appeared like cords(12), while spleen sections showed necrosis and infiltration of MNC(Fig. 13).

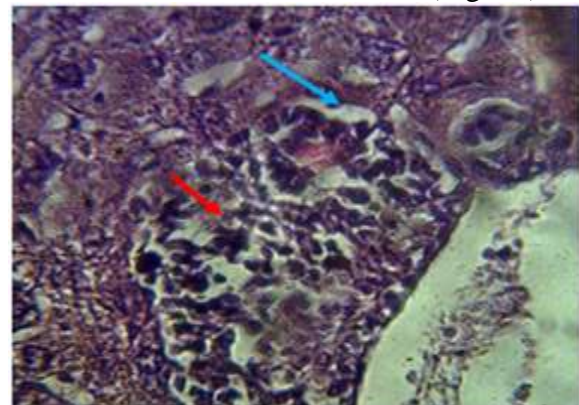


Figure 8. Histopathological changes in liver of infected animal with *P. chrysogenum* for two weeks shows granulomatous infiltration of inflammatory cells around the blood vessels (red arrow) and necrosis of hepatocytes (blue arrow) (H&E stain, X400).

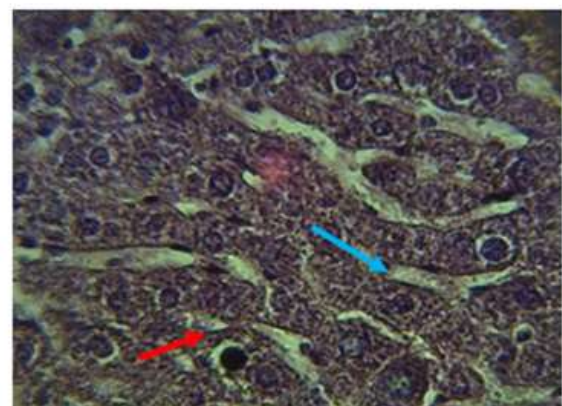


Figure 9. Histopathological changes in liver of infected animal with *P. chrysogenum* for two weeks shows apoptotic cells (red arrow) and arrangement of hepatocytes like cords (blue arrow) (H&E stain, X400) .

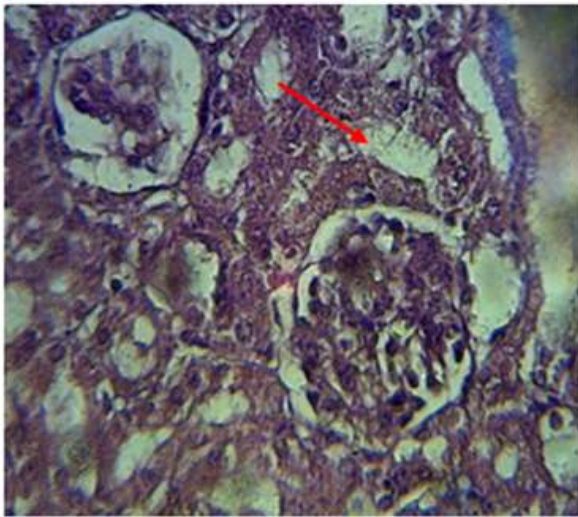


Figure 10. Histopathological changes in kidney of infected animal with *P. chrysogenum* for two weeks shows degeneration of epithelial cells of renal tubules (red arrow), infiltration of inflammatory cells in glomerulus and renal parenchyma with shrinkage of some glomeruli (blue arrow) (H&E stain, X400)

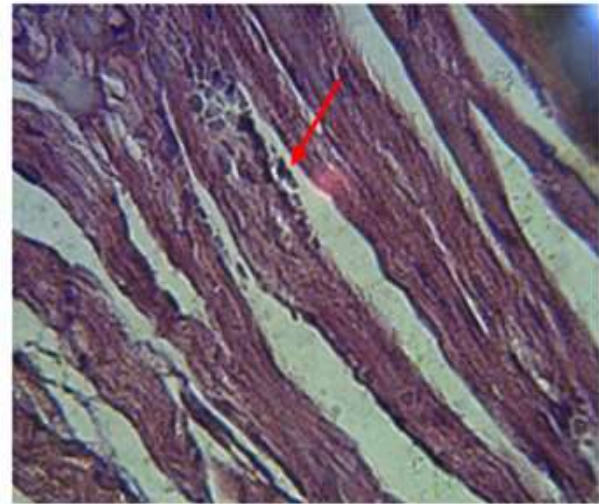


Figure 12. Histopathological changes in heart of infected animal with *P. chrysogenum* for two weeks shows infiltration of inflammatory cells and edema between myocardial fibers appearance like cords (red arrow) (H&E stain, X400).

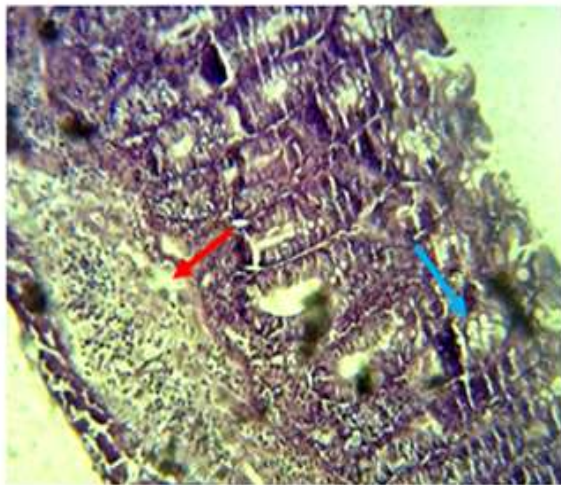


Figure 11. Histopathological changes in intestine of infected animal with *P. chrysogenum* for two weeks shows infiltration of inflammatory cells in mucosa and submucosa (red arrow) and hyperplasia of goblet cells (blue arrow) (H&E stain, X100)

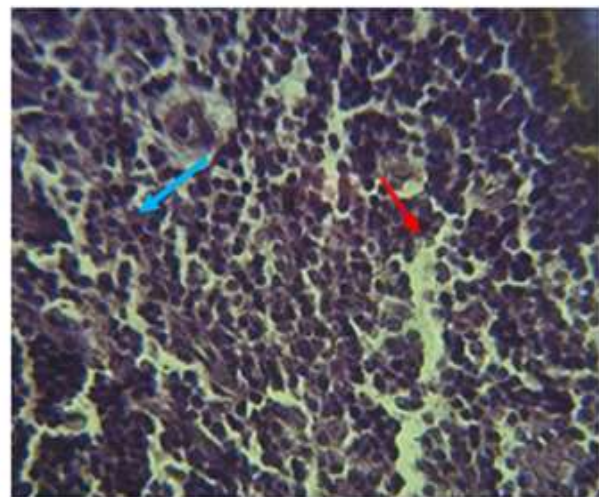


Figure 13. Histopathological changes in spleen of infected animal with *P. chrysogenum* for two weeks shows necrosis (red arrow) and infiltration of inflammatory cells (blue arrow) (H&E stain, X400)

Table 1. Results of enzymes activities in mice infected with *A. fumigatus* and *P. chrysogenum* conidia intraperitoneally and control group

Groups	Mean ± SE		
	ALT (U/L)	Creatinin (µmol/L)	Urea (µmol/L)
G1 (<i>A. fumigatus</i>)	21.70 ± 1.04 b	0.587 ± 0.03 b	57.91 ± 5.99 b
G2 (<i>P. chrysogenum</i>)	15.65 ± 0.78 c	0.928 ± 0.02 a	135.23 ± 8.75 a
G3 (Control)	45.50 ± 0.78 a	0.508 ± 0.02 c	37.21 ± 0.22 c
LSD value	2.587 **	0.068 **	18.025 **
P-value	0.0001	0.0001	0.0001

** (P<0.01)

Biochemical analysis: The results of the effect of *A. fumigatus* and *P. chrysogenum* infection on enzymes activities of liver and

kidney showed highly significant differences (P<0.01) among the groups. The results revealed very highly significant differences

($P < 0.01$) in the activity of ALT in animals of the 1st and 2nd groups as compared with control groups, while the biochemical tests of the kidney showed highly significant differences ($P < 0.01$) in creatinin and urea in the animals treated with *P. chrysogenum* when compared with the 1st and control groups (Table 1). This study was performed to compare of pathogenicity between two types of opportunistic fungi (*A. fumigatus* and *P. chrysogenum*) not only in the liver or Kidney but also in other internal organs of mice. This pathogenicity which responsible for alterations and tissue damage is associated with many types of virulence factors. As mentioned by numerous studies about the virulence factors of *A. fumigatus* which help this fungus in survival and persistence in the host resulting in tissue damage and disease (30). These factors include an ability to adhere to hosts' tissues through conidia of *A. fumigatus* are covered with hydrophobic proteins known as rodlets. These proteins are mediate adhesion of the conidia to albumin and collagen., Production of enzymes like proteases and phospholipases which degrade elastin present in lung tissue, Thermotolerance that can the fungi grow at temperatures of up to 55-77 °C through HSP 70, as well as Melanin production (14, 30). Moreover, Mycotoxins like Gliotoxin which is considered potent immunosuppressive and cytotoxic action and this may be discuss the reason of presence of apoptotic body in some samples of liver and this finding agree with the results of (19) who studied the impact of Gliotoxin in the liver of rats and found presence of apoptotic hepatic cell in the section. Moreover, *Penicillium* is large genus that more than 400 spp. have been described (32). Some of them can produce mycotoxins while another parts of them have chemical compounds used as enzymes and antibiotic (27). *P. chrysogenum* which is known previously *P. notatum* that have medical importance due to Penicillin production, also have the ability to produce some extrolites and

mycotoxins mainly PR-toxin as mentioned by (11). There are very few or rare reports about the pathogenicity of *P. chrysogenum* on the internal organs. Odebodea and Adekunlea (21) investigated the effect of this fungus in lung depending on doses and periods of time and found there was acute inflammation through a strong and rapid monocytes cells production in the lung. The results of current study indicated that there was severe pathological alterations in most organs taken in this experiment. This may be return to induction of oxidative damage and free radicals generation that reacted with cellular components leading to pathological changes. Also, if this isolate of *Penicillium* can produce mycotoxin particularly PR toxin, this will lead to tissue damage. This evidence is in consistence with Dubey et al., (9) who recorded damage in the vital internal organs, GIT perturbations, carcinogenicity, immunotoxicity, necrosis and enzyme inhibition due to action of PR toxin in case of ingestion food products enriched with this toxin. Moreover, the cytochrome P450 which is secreted from liver cells, renal tubular cells and lung cells can cause detoxification of toxin complex compound and this will lead to degeneration of organ cells as mentioned by Yassein and Zghair (31). In addition to histopathological study that carried out in this research, abnormalities on chemistry panel were also identified represented by significant differences ($P < 0.01$) in ALT, Creatinin and Urea in all groups for both fungi. This result was corresponding with histopathological findings due to the relationship with degree of organ damage, when the hepatocytes loss their functions and suffering from apoptosis this will lead to decline in ALT activity in serum. this evidence is in line with work of Shafiq and Al-Joofy (25) on nasal Aspergilliosis. But the result of kidney function markers in the group that treated with *P. chrysogenum* revealed high significant values when compared with other groups. This may be

return to increase lipid peroxidation in the kidney, then lead to renal insufficiency because these indices are considered a characteristic feature of renal injury. Based on the current findings, It can be concluded that although *A.fumigatus* and *P. chrysogenum* are saprophytic fungi, but they can be caused systemic mycosis with severe pathogenesis when inoculated intraperitoneally to mice in spite of the fact of *P. chrysogenum* produce antibiotic, So, further studies should be performed to determine the specific virulence factors in these fungi.

REFERENCES

1. Ahmed, N.Sh. and E.I. Al – Shamary. 2019. Antioxidant production from local fungal isolate. Iraqi Journal of Agricultural Sciences. 50(1):398-408
2. Al-Shamary, E. I. 2018. Production of single cell oil from local fungal isolate. Iraqi Journal of Agricultural Sciences. 49(4):527-533.
3. Al-Tameemi, H.A.A. and J.M. Khalaf. 2013. Isolation and identification of fungi from wounds and burns of human and farm animals. The Iraqi Journal of Veterinary Medicine, 37(2):251 -256
4. Bancroft, J. D. and A. Stevens. 1982. Theory and Practice of Histological Techniques. 2nd Ed. Churchill Livingstone, pp: 483-516
5. Böhma, J., B. Hoffa, M.C. O’Gorman, S. Wolfersa, V. Klíxc, D. Bingera, I. Zadrád, H. Kürnsteinerd, S. Pöggelerc, P.S. Dyerb .and U. Kücka, 2013. Sexual reproduction and mating-type-mediated strain development in the penicillin-producing fungus *Penicillium chrysogenum*. PNAS, 110 (4): 1476–1481
6. Chowdhary, A., K. Aqawal, and J.F. Meis, 2016 Filamentous fungi in respiratory infection what lies beyond aspergillosis and mucormycosis? PLoS Pathog.; 12(4):5491
7. Croft, C.A., L. Culibrk, MM. Moore, and S.J. Tebbutt. 2016. Interactions of *Aspergillus fumigatus* conidia with airway epithelial cells: A critical review. Front. Microbiol. 7:472.
8. Desoubeaux, G. and C. Gray. 2017. Rodent models of invasive Aspergillosis due to *Aspergillus fumigatus*: Still a long path toward standardization. Front. Microbiol. ,841
9. Dubey, MK, M. Aamir, M.S. Kaushik, S. Khare, M. Meena, S. Singh. and R.S. Upadhyay. 2018. PR Toxin –Biosynthesis, genetic regulation, toxicological potential, prevention and control measures: overview and challenges. Front. Pharmacol. 9:288
10. Dubie T., T. Sisay, M. Gebru, Y. Muktar, 2015. An insight review on the role of fungi in mastitis of dairy animals and its economical importance. The Journal of Veterinary Sciences. Photon 116, 440-445
11. Frisvad, J.C., J. Smedsgaard, T.O. Larsen. and R.A. Samson. 2004. Mycotoxins, drugs and other extrolites produced by species in *Penicillium* subgenus *Penicillium*. Studies in Mycology, 49: 201-241
12. Hassan, R.A. 2016. Effect of virulence *Aspergillus Fumigatus* isolate in liver of BALB/C mice. International Journal of Sciences: Basic and Applied Research (IJSBAR), 26(2):200-205
13. Hussain, H.T. 2017. Histopathological study on liver of mice during aspergillosis infection. Iraqi Journal of Sciences, 48(2A): 619-625
14. Iyalla, C. 2017. A Review of the virulence factors of pathogenic fungi. African Journal of Clinical and Experimental Microbiology, 18 (1): 53- 58
15. Kalleda, N, J. Amich, B. Arslan, S. Poreddy, K. Mattenheimer, Z. Mokhtari, H. Einsele, M. Brock, K.G. Heinze, and A. Beilhack. 2016. Dynamic immune cell recruitment after murine pulmonary *Aspergillus fumigatus* infection under different Microbiol. 7:1107
16. Laskaris, P., A. Atrouni, J.A. Calera C. d’Enfert, H. Munier-Lehmann, J.M. Cavaillon, J.P. Latgé and O. Ibrahim-Granet. 2016. Administration of zinc chelators improves

- survival of mice infected with *Aspergillus fumigatus* both in monotherapy and in combination with caspofungin. *Antimicrob Agents Chemother* 60:5631–5639
17. Mirkov, L., J. Zolotarevski, D. Glamočlija, M. Kataranovski, and A. Kataranovski. 2008. Experimental disseminated aspergillosis in mice: Histopathological study Aspergillose disséminée chez la souris : étude histopathologique. *Journal of Medical Mycology*, 18(2):75-82
18. Nadhom, B.N. 2018. Study of molecular composition of virulence organism isolated from bovine mastitis with biofilm production. *Iraqi Journal of Agricultural Sciences*, 49(5):840- 846
19. Nejak-Bowen, K.N., A.V. Orr, W.C. Bowen, and G.K. Michalopoulos, 2013. Gliotoxin-induced changes in rat liver regeneration after partial Hepatectomy. *Liver pathobiology. Liver Int.* 33: 1044–1055
20. Nurhayati, A., S. Berliana, M. Nelwida 2019. Protein efficiency in chapanes quail (*Coturnix-coturnix Japonica*) fed fermented palm kernel cake by(*Aspergillus niger*) *Iraqi Journal of Agricultural Sciences*,50 (Special Issue): 128-133
21. Odebode, A. and A. Adeunle, 2019. Immunologic and inflammatory responses in mice after intranasal instillation of spores of *Aspergillus* and *Penicillium* isolated from outdoor air in South West Nigeria. *Journal of Taibah University for Science*, 13(1):344-350
22. SAS. 2012. Statistical Analysis System, User's Guide. Statistical. Version 9.1th ed. SAS. Inst. Inc. Cary. N.C. USA
23. Saud, H.M. and M.A. Alaubaydi. 2019. Effect of clinical *Klebsiella pneumonia* extracted melanin on some immune aspects in mice. *Iraqi Journal of Agricultural Sciences*,50(1):241-247
24. Seyedmojtaba, S., J. Guillot, P. Pascal Arné, G. Sybren de Hoog. J.W. Mouton, and P.E. Verweij. 2015. *Aspergillus* and aspergilloses in wild and domestic animals: a global health concern with parallels to human disease. *Medical Mycology*, 53, (8): 765–797
25. Shafiq, S.A. and A.k. Al-Joofy,2010. Histopathological and enzymatic study on the effect of *Aspergillus fumigatus* in mice. *J Fac Med Baghdad Vol.* 52, No .4:480
26. Shibata, T., D.M. Habiél, A.L. Coelho, and C.M. Hogaboam. 2014. Axl receptor blockade protects from invasive pulmonary aspergillosis in Mice. *J Immunol* 2014; 193:3559-3565
27. Suleiman, E.A., S.B. Elmagboal, F. Elghazali, M.H.Salih, and O.M. Ahmed. 2015. Fatal pulmonary penicillosis in camels (*Camelus drome daries*). *British Microbiology Research Journal*7(3): 118-125
28. Van der Velden, W. J. F. M., N. M. A. Blijlevens, R. R. Klont, J.P. Donnelly, and P.E. Verweij. 2006. Primary hepatic invasive aspergillosis with progression after rituximab therapy for a post transplantation mphoproliferative disorder. *Ann Hematol* 85: 621–623
29. Washinton, WJ, A. Stephan, J. Willium, K. Elmer and W. Gail. 2006. *Konemans Color Atlas and Textbook of Diagnostic Microbiology*, 6th ed. pp:1152-1232
30. Woo, P.C.Y., S.K.P. Lau, C.C.Y. Lau, CCY. E.T.K. Tung, R.K.H. Yeung and Q. Hao. 2017. Mp1p homologues as virulence factors in *Aspergillus fumigatus*. *Medical Mycology*, myx052, <https://doi.org/10.1093/mmy/myx052>
31. Yassein, Sh.N. and Z.R. Zghair. 2012. Study of toxicity and pathogenicity of Aflatoxin B1 and G1 in mice. *Al-Anbar J. Vet. Sci.*, 5(1): 23
32. Yin, G., Y. Zhang, K.K. Pennerman, G. Wu, S. Sheng, H.J. Yu, W.M. Jurick, A. Guo, and J.W. Bennett. 2017. Characterization of blue mold *Penicillium* species Isolated from stored fruits using multiple highly conserved loci. *J. Fungi*, 3, 12:1-10