

EFFECT OF DEFFERENT LEVELS OF TURMERIC SUPPLEMENTATION WITH DIET ON HUMORAL IMMUNE RESPONSE TO NEWCASTLE AND INFECTION BURSAL DISEASE VIRUS AND HISTOPATHOLOGICAL CHANGES OF SOME INTERNAL ORGAN OF BROILER CHICKENS

I. M. Shihab

Assist. Lecturer

vet_ihsan@yahoo.com

Department of Pathology and Poultry Diseases, College of Veterinary Medicine, University of Baghdad-Iraq.

ABSTRACT

In this study, evaluated the effect of turmeric dietary addition on immune response against the Newcastle disease virus (NDV) and Infectious bursal disease (IBDV). and histopathological changes in some internal organs was evaluated in 42 day old broiler chicks. ninety-six Ross broiler chicks were reared from 1 to 42 days old and divided randomly into four groups, Feed and drinking water were offered ad libitum. Group1 (G1) received turmeric (0.2%), while group2 (G2) received turmeric (0.4%), Group3 (G3) received turmeric (0.6 %) and group4 (G4) was the control positive received basal diet . At the end of the trial five birds from each treatment were slaughtered for assessment of histological section, take same of organ (liver , spleen , and bursa of Fabricius) at 42 day. Results of ELISA test titer revealed differences among various treatment groups at the end of the experiment. mean ELISA test values of G2 revealed a higher significant at ($P < 0.05$) in antibody titers in comparison with other groups and control. specimen from liver ,spleen and bursa of fabricius were dissected out for histopathological examination and results of microscopic section showed increase in immune response of G2 chicken : of microscopic sections of G2 histopathological changes in the liver tissue revealed manifested by focal mononuclear cells aggregation and proliferation of kupffers cells and slight congestion of blood sinusoids and congestion of portal blood vessels with few infiltration of inflammatory cells .The intrahepatic bile ductless exhibited dilation and hyperplasia of their epithelial linings with slight per portal fibrosis compared with G1,G3 which showed no clear histopathological changes. The microscopic examination of the spleen revealed range from mild (G1 and G3) to moderate hyperplasia of lymphoid follicles in (G2) . histopathological changes in the bursa of fabricius were characterized by moderate follicular hypertrophy especially in G2 as compared with other treated group's and control .

Key words: Turmeric , broiler chicken , immune response.

شهاب

مجلة العلوم الزراعية العراقية – 48: (عدد خاص): 150-155 / 2017

تأثير مستويات مختلفة من الكركم مضافة الى العليقة في الاستجابة المناعية الخلطية لفايروس النيوكاسل والكمبورو والتغيرات المرضية لبعض الأعضاء الداخلية لدجاج اللحم

احسان محمد شهاب

مدرس مساعد

vet_ihsan@yahoo.com

قسم الامراض وامراض الدواجن- كلية الطب البيطري- جامعة بغداد- العراق.

المستخلص

اجريت هذه الدراسة لتقييم تأثير اضافة الكركم في الاستجابة المناعية الخلطية ضد فايروس مرض نيوكاسل (NDV) ومرض الكمبورو (IBD) والتغيرات المرضية في بعض الأعضاء الداخلية في دجاج اللحم بعمر 42 يوم . استخدم 96 فروج لحم نوع روز من (1-42) يوم، وزعت عشوائيا لاربعة مجاميع ، تم تقديم العلف وماء الشرب بصورة حرة وتم معاملتها كما يلي : المجموعة الاولى (G1) أضيف لها 0.2% مسحوق الكركم ، في حين المجموعة الثانية (G2) أضيف لها 0.4% مسحوق الكركم ، المجموعة الثالثة (G3) أضيف لها 0.6% مسحوق الكركم ، المجموعة الرابعة (G4) كانت مجموعة سيطرة موجبة أعطيت عليقة اساسية بدون اضافة . في نهاية التجربة تم ذبح 5 طيور من كل مجموعة لمعرفة التغيرات النسيجية ، تم اخذ بعض الاعضاء (الكبد والطحال وجراب فابريشيا) عند عمر 42 يوم . نتائج فحص الاليزا اشارت الى فرق معنوي ($P < 0.05$) بين مجاميع المعاملة المختلفة في نهاية التجربة. حيث اظهرت النتائج على وجود زيادة في معدل قيم فحص الاليزا للمجموعة الثانية (G2) وبشكل معنوي ($P < 0.05$) بالمقارنة مع المجاميع الأخرى ومجموعة السيطرة . إلا أن استخدام الكركم في المجموعة الثالثة (G3) لم يظهر فرق معنوي في قيم فحص الاليزا ، على الرغم من أنه لوحظ فرق عددي إيجابي بالمقارنة مع المجموعات الأخرى . تم اخذ عينة من الكبد والطحال وجراب فابريشيا واجراء الفحص النسيجي . نتائج فحص الأنسجة أظهرت زيادة في الاستجابة المناعية للدجاج في شريحة المجموعة الثانية (G2) أظهرت تجمع وانتشار خلايا احادية النواة وتكاثر وتجمع خلايا كوفر (kupffers cell). بالإضافة الى احتقان الاوعية الدموية الشعرية في (portal blood) وتجمع عدد قليل من الخلايا الالتهابية . واظهرت قوات الصفراء داخل الكبد توسع وتمدد وتضخم البطانة الظهارية مع تليف قليل بالمقارنة مع المجاميع المعاملة (G1 و G3) التي لم تظهر اي تغيرات نسيجية واضحة . شريحة الأنسجة للمجاميع المعاملة اظهرت تطور خفيف الى متوسط في المقطع النسيجي للطحال في (G1 و G3) وفرط تنسج في الجريبات المفاوية وخصوصا في (G2) . المقطع النسيجي لجراب فابريشيا أظهر زيادة متوسطة مع فرط نسيجي في الخلايا المفاوية في منطقة القشرة وخصوصا في المجموعة الثانية (G2) بالمقارنة مع المجاميع المعاملة ومجموعة السيطرة .

كلمات مفتاحية: الكركم، فروج لحم ،استجابة مناعية .

INTRODUCTION

Considered *turmeric curcuma longa* of perennial herbs, grown widely in tropical-climate countries, especially in Asia (China and India) and is growing at a height of three to five feet, considered active ingredient of turmeric spice is effective antioxidant and anti-inflammatory agent with hepatoprotective and anti-cancer as well as anti-bacterial properties (15). Nevertheless, Deshpande et al., (2), Confirmed high doses of turmeric or turmeric ethanol extract in rats and mice for long periods caused a reduction in body weight and hepatotoxic effects of the well necrotic foci. Similarly reported (8), use of turmeric or ethanol extract of *Curcuma* in protective doses against cancer may cause coagulative necrosis attached to with areas of parenchymal regeneration. Namagirilakshmi et al., (12) reported significant of the length increased intestinal villus in a dose related manner among the treatment groups compared with the control. Similarly, the bile duct epithelium primary and secondary folds count marked increases in 0.75 and 1.0% turmeric fed groups than other groups. The great benefit of plant bioactive material in feed animals increased appetite and feed consumed, improved the secretion of endogenous digestive enzymes, stimulated the immune response and increase the effectiveness of anti-bacteria, anti-viral and improve the actions of antioxidants. (20, 21). Also turmeric powder decreased ratio of triglycerides in the serum, but did not record any significant effect on the immune response against the Newcastle and Influenza virus and indicated the expected results for food supplementation of turmeric powder failed to any improvement in the performance except feed efficiency of broiler, however, feed treatment formed from the basal diet as control, 3.3, 6.6 and 10 g / kg turmeric powder added to the basal diet improves the positive influence of carcass abdominal fat, and the concentration of triglycerides in the serum at slaughter (13). (10,16) reported that turmeric powder has implications protective against Aflatoxin BRIR. Moreover, Wafaa et al., (22) showed that treatment of aflatoxicated birds either with Hydrated Sodium Calcium Aluminosilicate (HSCAS) or turmeric powder even their combination. One group was treated

with HSCAS a concentration of 0.5% and the other group fed a diet contained turmeric powder at a dose of 80 mg / kg, gave good protection against signs and lesions resulting from Aflatoxicosis with a significant improvement in body weight compared with the control group, while the group treated with both HSCAS and turmeric powder improved significantly in the weights of the body's organs ratio and immune response against Newcastle and biochemical measurements in the aflatoxicated chicken.

MATERIALS AND METHODS

Experimental animals: The experiment was conducted in a poultry breeding fields of the Animal Resources Department - college of Agriculture - University of Baghdad, after cleaning and disinfection by Formaline and Potassium Hypochlorite And left the hall closed for two days and then open all the doors and windows with running ventilator to get rid of the remaining toxic gases before the chicks entered the hall. Chicks (Ross 308, Syria origin) was purchased from hatchery Association of wade, AL-Rafidian – Bagdad /Abu graib. ninety six, (all Biosecurity protocols were applied). Allocated chicks to take randomly utilization within a completely randomized design (CRD) with four feed treatment from 0-42 days of age, the addition of two replicates (12 bird / pen). The experiment was designed diets as follows: G1 0.2% turmeric powder, G2 0.4% turmeric powder, G3 0.6% turmeric powder and G4 control. The birds were kept in floor pens (1.2×1.2m) in open sided house. The chicks in G1,G2.and G3 were vaccinated with ND (La Sota) via drinking water at day 15 followed by booster dose of Newcastle virus vaccine (La Sota) at day 25 and with IBD Gumbo L strain (Ceva-Hungary) at day (19) and G4 left without any vaccine as control. Blood samples of each group were aspirated from wing vein to determine antibody titers in serum against ND and IBD at days (42) using ELISA for (ND and IBD).

Diet composition and contents: The basal diet was formulated for broilers in which yellow corn and wheat were the major sources of energy, whereas the soybean and plant protein were the major sources of protein in this diet. This diet was fed to all groups. Other

ingredients were same as in the groups (Table 1). Nutritional requirements were adjusted according to the Nutritional Requirements Council (14). Starter: the chicks were fed on a starter diet for 1 to 28 days at the beginning of the experiment. Finisher: the chicks were fed from 29 days until the end of the experiment (day 42) (Table 1).

ELISA test (Synbiotics – USA)

The procedure used in this test was performed according to the manufacturer's instructions listed in the ProFLOK ELISA Kit Synbiotics–USA (19), which is a rapid serologic test for the detection of antibody in chicken serum samples. It was developed primarily to aid in the detection of pre and post-vaccination antibody levels in chickens.

Table 1. Composition of experimental diet used in this study

| Constituents | Percentages of ingredients in Starter | Percentages of ingredients in Finisher |
|------------------------------------|---------------------------------------|--|
| plant Protein (40 % protein) | 5 % | 5 % |
| Soybean meal(48 % protein) | 25 % | 24 % |
| Yellow corn | 39 % | 45 % |
| Wheat | 28 % | 22 % |
| Sun flower oil | 1 % | 2 % |
| Dicalcium phosphate | 1 % | 1 % |
| Minerals and vitamins mixture | 1 % | 1 % |
| | Chemical coponent | |
| Crude protein (%) | 21.94 | 20.07 |
| Metabolizable energy (kcal / kg) | 2921.9 | 3038.2 |
| Calcium (%) | 0.84 | 0.84 |
| Available phosphorus (%) | 0.42 | 0.42 |
| Lysine (%) | 1.20 | 1.02 |
| Methionine +Cysten (%) | 0.82 | 0.78 |

Provided per kg of diet :vitamin A :22000IU, D3:60, E:60mg, B1:60mg, B2:140mg, B6:80mg, B12:700mcg , Biotin:2.00mcg, Folic acid:20mg , Vitamin E K3:5mg , Choline chloride:7.5mg , Cu:200mg , Mn:1.6mg, Zn:1.2mg , Fe:1.0mg , I:20mg , Se:5mg, Calculated composition of experimental diets according to (14).

Histopathological examination:

The specimens were taken at 42 days old with dimensions (1cubic cm) from the liver, spleen and bursa of fabricius, the tissues were fixed in 10% buffer formaldehyde solution immediately after removing. After 72 hrs of fixation, the specimens were washed with tap water and then dehydration was by upgrading alcoholic concentration of 70% to absolute

100% for 2 hrs in each concentration . Clearance was done by xylo, then the specimens were infiltrated with semi-liquid paraffin wax at 58 C° on two stages, then blocks of specimens were made with paraffin wax and sectioned by rotary microtome at 5µm. All tissue were stained with hematoxylin and eosin (H & E) stain and the histopathological changes were observed under a compound microscope (9).

Statistical analysis:

Used variance analysis to analyze the data (17) and means significant separated by Duncan-multiple test (3).

RESULTS

Mean antibody titer values against NDV for group 1,2,3, and 4 were 3820.60, 6061.40, 4429.00 and 168.00, respectively (Table 2). Table 2 shows that antibody titers were significantly higher when broilers were fed by turmeric in G2 ($p < 0.05$) than the control group. The Mean antibody titer values against IBD for group 1,2,3, and 4 were 1350, 6696, 4487 and 443, respectively (Table 2). Mean antibody titer against IBD was higher for G2 than other groups and control. These results indicate that *Curcuma longa* (turmeric) has improved immunity by increasing the antibody titer against ND and IBD Antibody.

Table 2. The means of Ab titer at 42 days old of chicken against NDV and IBD .(Mean ± SE)

| Groups | AB titer | |
|--------|-------------------------------|----------------------------|
| | NDV | IBD |
| G1 | 3820.60 ± 120.75 ^c | 1350 ± 882.5 ^{bc} |
| G2 | 6061.40 ± 28.05 ^a | 6696 ± 933.5 ^a |
| G3 | 4429.00 ± 22.06 ^b | 4487 ± 1410.6 ^b |
| G4 | 168.00 ± 16.8 ^d | 443 ± 61.7 ^c |

Small letters between groups (column) denoted significant differences ($p \leq 0.05$). G1 (0.2%) turmeric, G2 (0.4%) turmeric , G3 (0.6%) turmeric , G4 basal diet (vaccinated) , Anti body (AB).

Histopathological study

Control group

Liver: The tissue section of (liver, spleen and bursa of fabricius of the control group showed normal histology structure (Fig1, 2 ad 3) respectively.

Treated groups

Liver: Tissue microscopic sections of G2 showed focal mononuclear cells aggregation

and proliferation of kupffers cells and slight congestion of blood sinusoids (Fig.4). congestion of portal blood vessels with few infiltration of inflammatory cells (Fig.5).The intrahepatic bile ductless exhibited dilation and hyperplasia of their epithelial linings with slight per portal fibrosis (Fig.6) as compared with G1, G3 which showed no clear histopathological changes.

Spleen: The histopathological changes noticed in the treated groups range from mild (G1 and G3) to moderate hyperplasia of lymphoid follicles (G2) Fig.7

Bursa of Fabricius The microscopic section
:Were characterized by moderate follicular

hypertrophy especially of G2 as compared with other treated group's (G1 and G3) Fig.8.

DISCUSSION:Serum antibody level is the indicator of humoral immunity. These results showed higher significantly ($p < 0.05$) in antibody titer in group G2 receiving turmeric 0.4% than other groups and G4, suggesting that Curcumin has been reported to possess Many pharmacological properties including anti-inflammatory, anti-microbial, anti-viruses, anti-fungal, anti-oxidants and wound healing properties (6). In addition turmeric powder have effectiveness Immunomodulatory activities through which regulates the effectiveness of each of (T, B, Macrophages, hetrophils, natural killer and dentric) cells

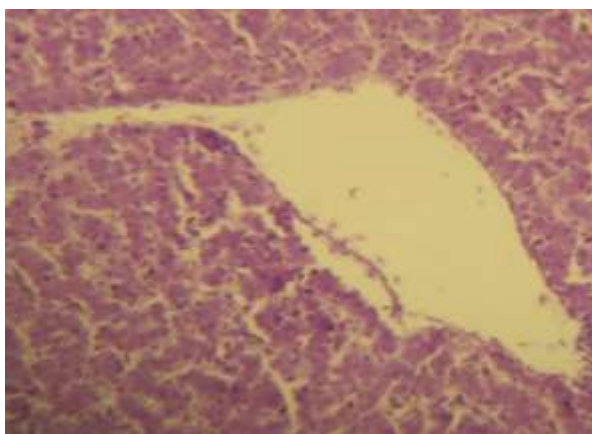


Plate 1: Normal histological structure of liver in control group (H&E 400X).

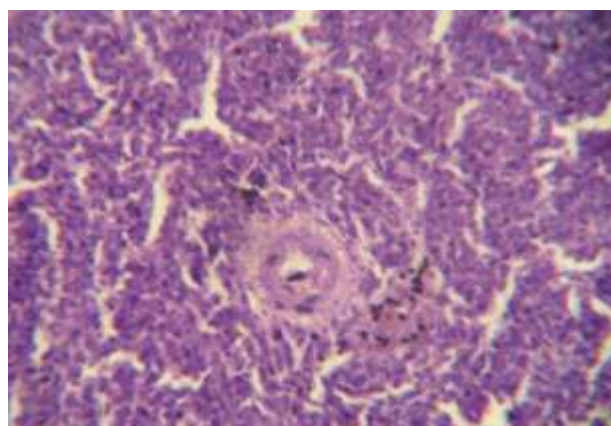


Plate 2: spleen section of control group showing normal histological structure (H&E 400X)

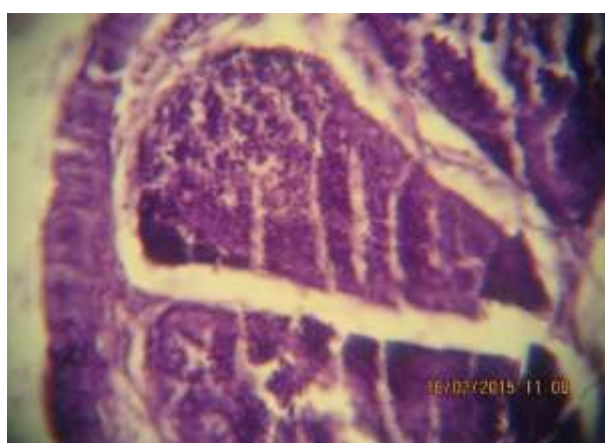


Plate 3: Buras of fabricious of control group showing normal histological structure (H&E400X).

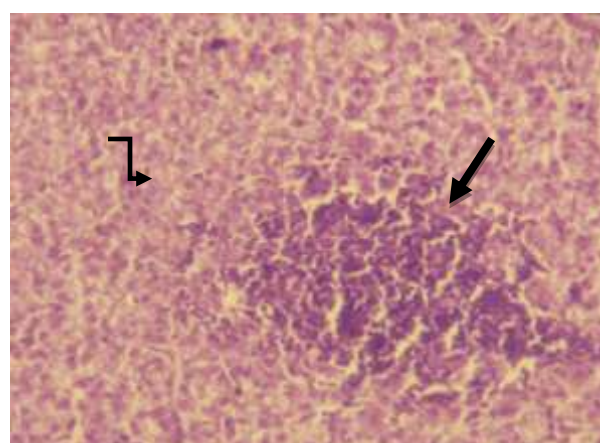


Plate 4: liver section of G2 showing focal mononuclear cell aggregation () and proliferation of kupffers cells () (H&E400X)

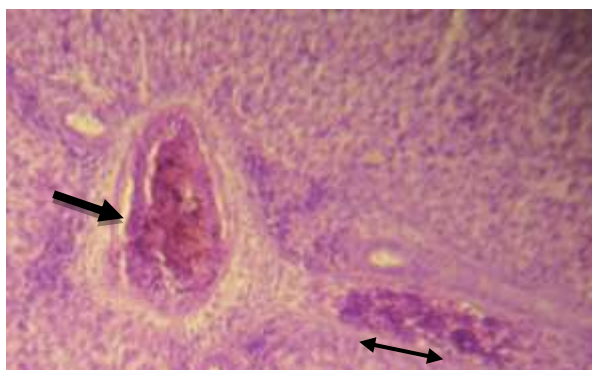


Plate 5: liver section of G2 showing congestion of portal blood vessels () with few infiltration of inflammatory cell () (H&E400X)

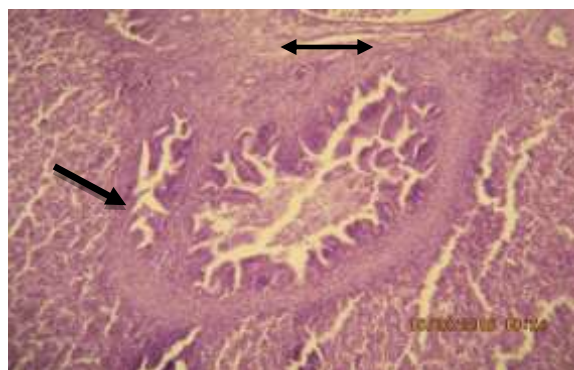


Plate 6: liver section of G2 showing intrahepatic bile ductules dilation and hyperplasia of their epithelial linings with () slight periportal fibrosis() (H&E400X).

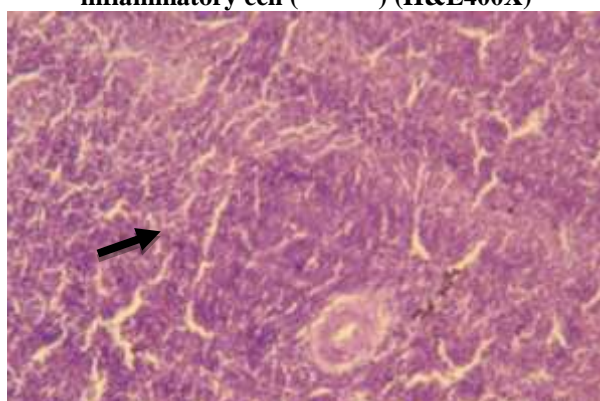


Plate 7: spleen of G2 showing hyperplasia of lymphoid follicles () (H&E400X).

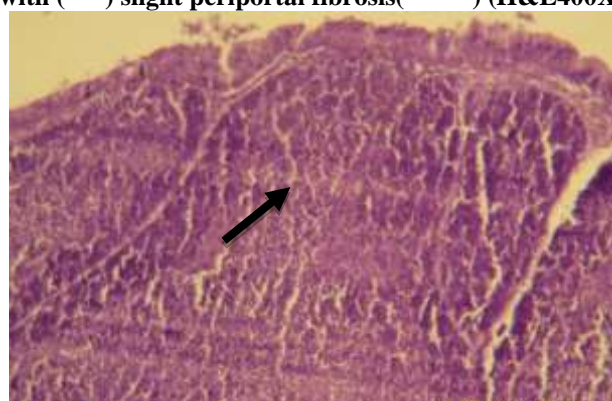


Plate 8: bursa of Fabricius of G2 showing moderate follicular hypertrophy () (H&E400X).

Many researchers confirmed presence of significant differences ($P < 0.05$) in means of antibodies titre for the treated groups with Neem dose of 8g / kg feed and turmeric powder at a dose of 2 g / kg feed. Also vitamin E at a dose of 0.2 g / kg and in combination with turmeric (*curcuma longa*) compared to the control group. Other results proved higher immune response as a result of feed additive of turmeric in broiler (11). On the contrary, it was recorded the highest significantly immune response in the chicken treated with turmeric and vitamin E against Newcastle virus. These results disagree with Shivappa et al., (18) who found the Used of turmeric powder with vitamin E has a significant effect on the means of HI antibodies titre. Similarly Nazarene et al., (13) found no significant impact of turmeric powder 3.3, 6.6 and 10 g/kg has been observed in antibody titre against viruses Newcastle and Influenza. The result of histological sections of the liver in present study was in agreement with El-Far (4) observed addition of turmeric 1.0% to duckling's ration were induced a protective effect against aflatoxicosis and

enhancement of phagocytosis in the liver . Similarly result of this study is agreed with AL-Sultan and Gameel (1) who reported mononuclear cells infiltration of parenchymal and portal area and congestion of portal vessels in liver tissue sections of broiler chickens diet treated with turmeric (*Curcuma longa*) in concentrations of 0.0, 2.5, 5.0 and 10%.

REFERENCES

- 1.AL-Sultan S.I. and A.A Gameel 2004 . Histopathological changes in the livers of broiler chicken supplemented with turmeric (*Curcuma longa*). International Journal of Poultry Science 3, (5): 333-336.
- 2.Deshpande, S.S., V.S. Lalitha, A.D. Ingle, A.S. Raste, S.G. Garde and G.B. Maru. 1998. Subchronic oral toxicity of turmeric and ethanolic turmeric extract in female mice and rats. Toxicol. Letters, 95:183-193.
- 3.Duncan, D.B. 1955 . Multiple Range and Multiple F tests. Biometrics, 11 : 1- 42.
- 4.El-Far, A. H.2008. The Biochemical Protective Role of some Herbs Against Aflatoxicosis in Ducklings. Ph.D Dissertation. Fac. Vet. Med., Alex.

5. Ganesh C.J., and B.A Bharat, 2007. "Spicing Up" of the immune system by curcumin. *J. Clin. Immunol.* 27, 19-35.
6. Garcea G., D.P. Berry, D.J. Jones, R. Singh, and A.R. Dennison, 2005. Consumption of the putative chemopreventive agent curcumin by cancer patients: assessment of curcumin levels in the colorectum and their pharmacodynamics consequences. *Cancer Epidem. Biomarker. Prev.* 14, 120-125
7. Jagdeeswaran, 2007. Exploration of Growth Promoting and Immunomodulating Potentials of Indigenous Drugs in Broiler Chicken Immunized Against Newcastle Disease. Ph.D., Dissertation Submitted To Tanuvas .
8. Kandarkar, S.V. , S. Sawant, A.D. Ingle, S.S. Deshpande and G.B. Mary, 1998. Subchronic oral hepatotoxicity of turmeric in mice – histopathological and ultrastructural studies., *IND. J. Exp. Biol.*, 36, : 675-679.
9. Luna, L.G. 1968. "Manual of Histologic Staining Methods of the Armed Force. Institute of Pathology". 3rd Ed. McGraw-Hill, New York.
10. Manafi, M., H.D. Narayanaswamy and N. Pirany. 2009. *In vitro* binding ability of mycotoxin binder in commercial broiler feed. *Afr. J. Agr. Res.*, 4 (2): 141-143.
11. Mehala, C. and M. Moorthy, 2008. Effect of aloe vera and curcuma longa on carcass characteristics and biochemical parameters in broilers. *International Journal of Poultry Science*, 7 (9): 857-861.
12. Namagirilakshmi S., P. selvaraj, K. Nanjappan, S. Jayachandran and P. Visa, 2010. Turmeric (*CurCuma longa*) as an alternative To in-feed antibiotic on The gut health of broiler chickens. *Tamilnadu J. Veterinary & Animal Sciences* 6 (3) 148-150, May .
13. Nazarene, S.A. Tabeidian, M. Toghyani, G. Ghalamkari and M. Toghyani, 2011. Effect of turmeric powder on performance, carcass traits, humoral immune responses, and serum metabolites in broiler chickens. *Journal of Animal and Feed Sciences*, 20, 389–400
14. NRC. 1994. Nutrient Requirements of Poultry, National Research.
15. Pal, S., T. Choudhuri, S. Chattopadhyay, A. Bhattacharya, G.K. Datta, T. Das and G. S.A. 2001. Mechanisms of curcumin-induced apoptosis of Ehrlich's ascites cacinoma cells. *Biochem. Biophys. Res. Commune.*, 2: 288: 658-65.
16. Ranges, N. And M.G. Ahangaran, 2011. Evaluation of turmeric extract on performance indices impressed by inducing aflatoxicosis in broiler chickens. *Toxicol. IND. Hlth.*, 27 (10): 956-960.
17. SAS. 2012. SAS User, s Guide for personal, computers. SAS. Institute Inc., Cary ,N.C. USA.
18. Shivappa Nayaka, H.B., B. Umakantha, and S. Wilfred Reuben, 2012. Effect of neem, turmeric, vitamin E and their combinations on immune response in broilers. *Global Veterinaria* 9 (4): 486-489.
19. Synbiotic - Corporation 2005. Newcastle disease virus antibody test kit. Proflock R. Plus. Item No 96-95 33. Frontera San Diego, CA 92127. U.S. Vet LIC No312.
20. Toghyani M., M., A.A. Toghyani, G. Gheisari, S. Ghalamkari and Eghbalsaeid. 2011. Evaluation of cinnamon and garlic as antibiotic growth promoter substitutions on performance, immune responses, serum biochemical and hematological parameters in broiler chicks. *Livest. SCI.* 138, 167-173
21. Toghyani M., M., A. A. Toghyani, G. Gheisari, M. Ghalamkari and Mohammadrezaei. 2010. Growth performance, serum biochemistry and blood hematology of broiler chicks fed different levels of black seed (*Nigella sativa*) and peppermint (*Mentha piperita*). *Livest. SCI.* 129, 173-178
22. Wafaa A. Abd El-Ghany, M.E. Hatem, and M. Ismail, 2013. Evaluation of the efficacy of feed additives to counteract the toxic effects of aflatoxicosis in broiler chickens. *International Journal of Animal and Veterinary Advances* 5 (5): 171-182.