

COMPARATIVE STUDY OF HISTOPATHOLOGICAL CHANGES BETWEEN NANO-BORON AND BORON IN SMALL INTESTINE OF LAYER CHICKENS

Abtisaam J. A.
Assist. Prof.

A. Q. Al-Awadi
Assist. Prof.

B. H. Ali
Prof.

Coll. Vet. Med., University of Baghdad
ebtisaam.j@covm.uobaghdad.edu.iq

ABSTRACT

The aim of this study was to compare the effect of boron and nanoboron" on histomorphology of the small intestine in layer chickens. 210 day-old chicks were used and were randomly assigned to seven equal groups. The experiment, groups were exposed to both normal boron and nano-boron as follows:G1 received 15 mg/L of boron in their drinking water, G2 got 25 mg/L, G3 got 45 mg/L, while groups nano boron as following G4 got 15 mg/L, G5 got 25 mg/L, G6 got 45 mg/L of nano-boron, and G7 was not given any treatment. By using a light microscope, the histomorphology result of intestine was examine to determine the villi's height, thickness, crypt depth, and muscle thickness. The measurements of villi height, crypt depth, and muscle thickness showed a significant difference ($P \leq 0.05$) between all treated groups (nanoboron at G5,G6 than normal boron) in comparison with control group, with the highest mean in G6(NB) in all measures of intestine. The findings of this study concluded that the adding of "boron and nanoboron" to consumption water improved the structure of intestine, and this was particularly evident at high nanoboron concentrations.

Keywords: intestinal health, histomorphology, poultry, minerals

علي وآخرون

مجلة العلوم الزراعية العراقية -2023: 54(3):724-729

دراسة مقارنة للتغيرات النسيجية المرضية بين نانو بورون والبورون في الأمعاء الدقيقة للدجاج للبياض

بلقيس حسن علي
أستاذ

احمد قاسم العوادي
استاذ مساعد

ابتسام جواد علي
استاذ مساعد

كلية الطب البيطري / جامعة بغداد

المستخلص

تهدف الدراسة الحالية مقارنة تأثير البورون والنانوبورون" على الشكل النسيجي للأمعاء الدقيقة في الدجاج البياض. تم استخدام 210 فراخ بعمر 1 يوم واحد وتم تقسيمها عشوائيا إلى سبع مجاميع متساوية. تعرضت المجموعات لكل من البورون الطبيعي والنانوي على النحو التالي G1 اعطيت 15 ملغم / لتر من البورون و G2 اعطيت 25 ملغم / لتر من البورون و G3 اعطيت 45 ملغم / لتر من البورون اما G4 اعطيت 15 ملغم / لتر و G5 اعطيت 25 ملغم / لتر و G6 اعطيت 45 ملغم / لتر من النانوبورون اما G7 لم تعطى اي معاملة. باستخدام المجهر الضوئي، تم فحص المظهر النسيجي للأمعاء لتحديد ارتفاع الزغب وسمكه وعمق السرداب وسمك العضلات أظهرت قياسات ارتفاع الزغب وعمق السرداب وسمك العضلات فرقا معنويا ($P \leq 0.05$) بين جميع المجموعات المعالجة (نانوبورون في G5 و G6 و البورون الطبيعي) مقارنة بمجموعة السيطرة، مع أعلى متوسط في G6 (النانوبورون) في جميع مقاييس الأمعاء. خلصت نتائج هذه الدراسة إلى أن إضافة "البورون والنانوبورون" إلى ماء الشرب أدى إلى تحسين تركيب أنسجة الأمعاء لاسيما التركيز العالي للنانو بورون.

الكلمات المفتاحية : صحة الأمعاء، علم الأنسجة، الدواجن، المعادن

INTRODUCTION

The requirement for rare mineral elements has increased due to the increase in production and growth rates, these elements are crucial nutrients for the growth and production of poultry, and a shortage of one or more of these nutrients causes a serious decline in the health of the birds (1). One of these is boron, which has been recognized as a necessary component for plants since 1923, early in the 1980s, the impact of boron on a variety of bioactivities and metabolic processes, including enzymes and steroid hormones, led to the discovery of its involvement in human and animal nutrition (19). Additionally, it plays a crucial and effective part in the metabolism of calcium, phosphorus, and magnesium and in the development and growth of poultry birds (13). Nanotechnology is one of the many advancements that the poultry business has witnessed in recent years. This exciting and rising technology has the potential to revolutionize the poultry industry globally. Nanoparticles typically range in size from 1 to 100 nm. In the field of breeding poultry, this method is applied on a large scale, these nanoparticles can therefore transmit the feeding ingredients across tissues and cell membranes by bypassing normal distribution mechanisms. (1). Because of its extremely effective characteristics, substantial surface area, and superior absorption capacity when compared to boron element, nano-boron has been exploited as a novel source for boron. The conclusions reached by Mousa and Ali (16). The broiler chicks' drinking water contained nano-boron particles, growth performance significantly improved compared to the control group. Modern strains most vulnerable to treatment for poultry from rare mineral elements became very high due to their rapid growth and rate, besides it has a high metabolism to be highly productive of both meat and eggs (1,11). Due to the dearth of research on the use of nano-boron particles in poultry diets, this study was carried out to ascertain the best concentrations of boron and nanoboron particles added to poultry diets that we might advise and to investigate the impact of these particles on the intestinal performance of layers chickens.

MATERIALS AND METHODS

Birds management: The experiment was conducted at the poultry farm of Veterinary Medicine in University of Baghdad. Chicks were supplied by the appropriate lighting system, clean wood shaving as litter and feed and water which were provided (*ad libitum*) (3,4,5).

Study design = Two hundred and ten one day old chicks were weighted and allocated into seven groups at random. The experimental groups underwent the following exposure throughout the experiment.: (G1,G2,G3) treated with (15, 25 and 45) mg/ml boron respectively in drinking water and (G4,G5,G6) treated with (15, 25 and 45) mg/ml nano boron respectively in drinking water and control group G7 not treated. The experimental period lasted for 40 days. In order to identify the "crystalline structure" of the nano-boron, a laboratory X ray diffractometer (XRD 6000) was used to analyze the boron nanoparticles that Commercial Corporation had bought from China (14).

Sampling: The tissue samples were fixed by 10% formalin for two days, then prepared for paraffin embedding technique and sectioned at six μm with rotary microtom. The organs sections have stained with hematoxylin and eosin stain (7). The tissue were examined and measured the villi height, thickness and depth of crypts by The Future Win Joe microscopic camera was used for light microscopy and microphotography, and the Fiji image analyzer system was used to evaluate and score the photos (6,22).

Statistic evaluation

Using SAS, data analysis was done statistically to determine whether there were significant differences between the means, a one-way ANOVA and least significant differences (LSD) (18).

RESULTS AND DISCUSSION

The results in the current study revealed a significant difference ($P \leq 0.05$) between all treated groups (nanoboron (822.56 ± 36.06 , 781.78 ± 11.42 , 748.04 ± 28.36) then normal boron (670.58 ± 40.05 , 515.66 ± 26.59 , 479.63 ± 13.26) in villi height compared with control group, also there's a significant difference ($P \leq 0.05$) between groups treated

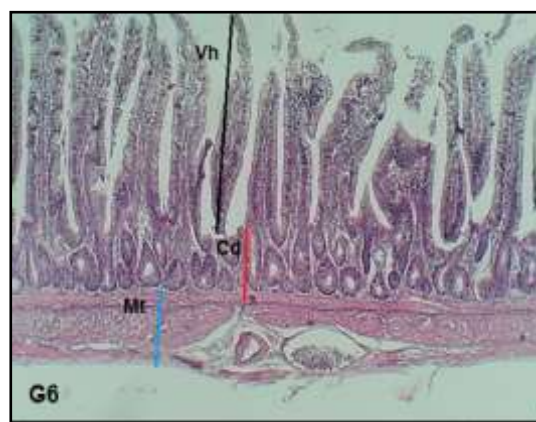
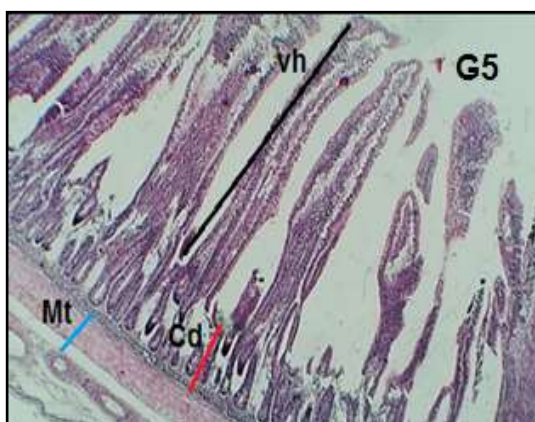
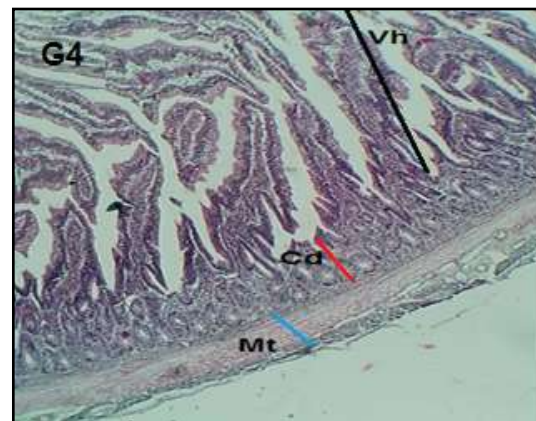
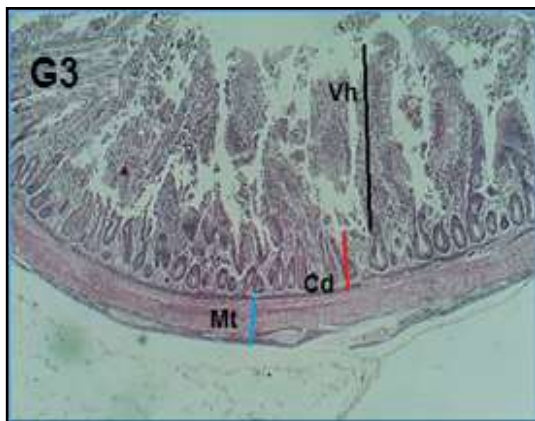
with nanoboron G6 and G5 compared with , G3,G2,G1,the highest mean of villi height in G6(NB) (822.56±36.06) followed by G5(781.78±11.42a) , the results of Depth of the crypts revealed significant difference(P≤0.05) between nanoboron groups G6 and boron group G1 also found significant difference(P≤0.05)between G6, G5, G4 and G3compared with G7 control group ,

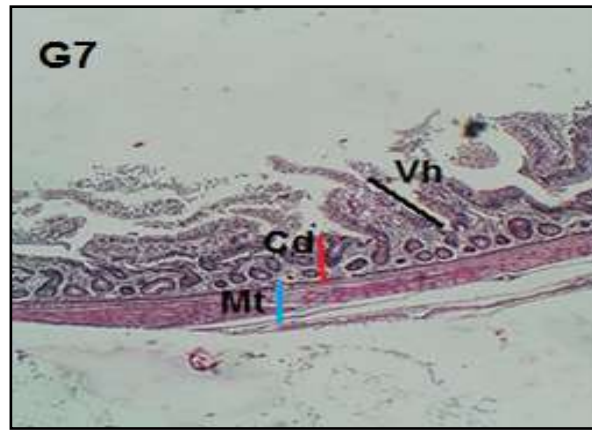the highest mean of depth of the crypts in G6(NB) (144.93±10.83a) finally the results of muscle thickness revealed significant difference(P≤0.05) between groups treated with nanoboron G6 , G5 , G4, compared with boron groups(G2,G1and G7 control group) also the highest mean of muscle thickness in G6(NB) (208.04±6.65a) with significant difference(P≤0.05) compared with all groups

Table 1. Histomorphological of small intestine in layer chickens broiler treated with different concentrations of Boron and Nanoboron (Mean ± SE)

Groups	Villi height	Depth of the crypts	muscle thickness
1	479.63±13.26c	120.94±11.12bc	118.15±6.36d
2	515.66±26.59c	126.41±4.64abc	121.20±11.93d
3	670.58±40.05b	138.47±6.66ab	125.66±16.98cd
4	748.04±28.36ab	138.08±8.19ab	153.44±5.38bc
5	781.78±11.42a	140.94±5.24ab	176.38±12.41b
6	822.56±36.06a	144.93±10.83a	208.04±6.65a
7	326.16±16.60d	104.06±7.85c	101.33±8.16d
LSD	80.79	23.12	28.70

Means in the same column with a different letters are substantially different (P≤0.05)





Figures 1 . Histomorphological of small intestine of boron groups(G1,G2,G3) and nanoboron groups (G4,G5,G6) and control group(G7)

The main digestive and immunological organ, the intestine, not only absorbs nutrition but also guards against pathogens and antigens from entering the body (20). Previous research demonstrated that the breakdown of the intestinal mucosal can result in the transfer of pathogenic bacteria and toxins to the systemic circulation, which then triggers the release of numerous proinflammatory cytokines that may produce harmful byproducts like oxygen free radicals, which ultimately lead to organ dysfunction (7,8). A type of trace element called boron has a wide range of biological applications and is primarily absorbed by digestive system, respiratory tract, and skin harm(1,2) . Previous studies have demonstrated that boron at low doses can prevent the apoptosis of bone and thymus cells, however boron at high doses had the reverse effects. (9, 26) In current research , we found that the nano boron and normal boron caused improvement in villi ,crypt depth and muscle thickness and this result is more obvious in 45 mg/L of nanoboron followed by 25 mg/L of nanoboron group, which indicates improvement of the intestinal mucosal barrier function(22). Because of its extremely effective characteristics, substantial surface area, and superior absorption capacity when compared to boron element, nano-boron has been exploited as a novel source for boron (16) Boron may have an impact on how well cells act as antioxidants, a sufficient amount of boron could boost the ability to remove free radicals and decrease lipid peroxidation by increasing the activity of antioxidant enzymes (12). Also, boron may have an impact on "the mitochondrial pathway's caspase-3 gene

expression". which caspase-3 is essential for this pathway and that boron suppresses gene production at low doses while promoting it at large doses.(15,24).The doses of 45 and 25mg/l consider low doses because another studies by Sun *et al.*(23) found that high doses,80, 320 and 640 mg/L of boron caused destruction of the intestinal mucosal barrier function , previous research have shown that boron has a role a function in the growth and development of birds(10,25). Hypothesizing boron's potential role in cell development and proliferation(25). According to Park *et al.* (17), borate was substantially mitogenic at relatively low doses but lethal at high quantities. in the current study, indicating that nano boron activated high-mitotic-activity immature stem cells in the basal crypt compartment. This may suggest that nanoboron has a positive impact on the intestine's absorption surface in chickens and improves the morphological characteristics of the intestinal mucosa.

REFERENCES

- 1.Abbas, N. K. and N. A. Ali. 2019. Effect of adding different levels of Nano-boron particles to the diet in some of the productive traits for the broiler chicken (Ross 308). *Plant Archives* . 19 (2): 3446-3452.
- 2.Abbaspour, N., R. Hurrell and R. Kelishadi. 2014. Review on iron and its importance for human health. *J. Res. Med. Sci.* 19: 164 – 174.
- 3.Abdullah , S.M.,S.Abdulmaged,S.Hamad, and A. J. Ali. 2022. "Comparative study between phytoenic and E.coli vaccine in broilers. *Iraqi Journal of Agricultural Sciences*.53(1):157–163.
<https://doi.org/10.36103/ijas.v53i1.1520>

4. Ali, J. and B. H. Ali. Ali. 2019. Inflammatory reaction against *Mycoplasma gallisepticum* infection in broiler. Iraqi Journal of Agricultural Sciences .50:(5)1432-1438. <https://doi.org/10.36103/ijas.v50i5.811>
5. Ali, B. H., A.J. Ali and E.H. Yosif. 2020. Isolation and molecular characterization of *Mycoplasma synoviae* from infected chickens with respiratory signs. Iraqi Journal of Agricultural Sciences. 51(5):1321–1328. <https://doi.org/10.36103/ijas.v51i5.1157>
6. Bancroft, JD and G. Marilyn. 2008. Theory and Practice of Histological Techniques. 1st Ed., London, Elsevier Limited. :168-173
7. Beattie, G. and A. Siriwardena, 2000. Bacterial infection and extent of necrosis are determinants of organ failure in patients with acute necrotizing pancreatitis. Br. J. Surg. 87(2):250
8. Chen, X., H.X. Zhao, X.S. Fu, C.P. Li and X.L. Zhong. 2012. Glucagon-like peptide 2 protects intestinal barrier in severe acute pancreatitis through regulating intestinal epithelial cell proliferation and apoptosis. Pancreas. 41(7):1080-5
9. Cheng, J., K. Peng, E. Jin, Y. Zhang, Y. Liu, N. Zhang, H. Song, H. Liu and Z. Tang. 2011. Effect of additional boron on tibias of African ostrich chicks. Biol. Trace Elem. Res. 144(1-3):538-49.
10. Eckhert, C. D. 1998. Boron stimulates embryonic trout growth. J. Nutr. 128(12):2488-93
11. Eren, M. and F. Uyanik. 2007. Influence of dietary boron supplementation on some serum metabolites and egg-yolk cholesterol in laying hens. Acta Vet. Hung. 55(1):29-39
12. Hu, Q., S. Li, E. Qiao, Z. Tang, E. Jin, G. Jin and Y. Gu. 2014. Effects of boron on structure and antioxidative activities of spleen in rats. Biol. Trace Elem. Res. 158(1):73-80
13. Hunt, C.D. 2012. Dietary boron: progress in establishing essential roles in human physiology. Journal Trace Elem. Med. Biol. 26: 157-160.
14. Kasper, J.S., C.M. Lucht and D. Harker. 1950. The crystal structure of decaborane, B₁₀H₁₁. Acta Cryst. 3:436-455
15. Lakhani, S. A., A. Masud, K. Kuida, G. A. J. Porter, C.J. Booth, W.Z. Mehal, I. Inayat and R. A. Flavell. 2006. Caspases 3 and 7: key mediators of mitochondrial events of apoptosis. Science. 3(11):847-51
16. Mousa, D.M. and B. Ali. 2018. Impact of boron and nano-boron on the heterophil/lymphocyte ratio and histopathological changes of liver and kidney in broiler chicken infected with *Escherichia coli*. Basrah. J. Vet. Res. 17(3):290–306.
17. Park, M., Q. Li, N. Shcheynikov, S. Muallem and W. Zeng. 2005. Borate transport and cell growth and proliferation. Not only in plants. Cell Cycle. 4(1):24-6
18. SAS. 2012. Statistical Analysis System, User's Guide. Statistical. Version 9.1th ed. SAS. Inst. Inc. Cary. N.C. The
19. Scorel, R. D. 2011. Drinceanu, Rodica Criste, Lavinia STEF, C. Julean, Borul în hrana animalelor si an omului, Ed. Eurobit, Timisoara . 17(3):290–306.
20. Simaz, Ö., B. H. Koksals, A. Tekeli, and A. G. Yildiz. 2021. Effects of boron supplementation alone or in combination with different vitamin D₃ levels on laying performance, eggshell quality, and mineral content and fatty acid composition of egg yolk in laying hens. Journal of Animal and Feed Sciences. 30(3):288-294.
21. Sızmaz, O. and G. Yildiz. 2016. Influence of dietary boric acid and ascorbic acid on performance, egg traits, cholesterol and bone parameters of laying hens . Ankara Üniversitesi Veteriner Fakültesi Dergisi .63: (2) 151-156 .
22. Suad, K. A., J. S. H. Al-Shamire, and A. Dhyaa. 2018. Histological and biochemical evaluation of supplementing broiler diet with β-hydroxy-methyl butyrate calcium (β-HMB-Ca). Iranian Journal of Veterinary Research. 19:(1), 27-30
23. Sun, P., Y. Luo, X. T. Wu, A.R. Ansari, J. Wang, K. Yang, K. Xiao and K. Peng. 2016. Effects of supplemental boron on intestinal proliferation and apoptosis in African ostrich chicks. Int. J. Morphol. 34(3):830-835
24. Tang, J., X.T. Zheng, K. Xiao, K.L. Wang, J. Wang, Y.X. Wang, K. Wang, W. Wang, S. Lu, K.L. Yang, P.P. Sun, H. Khaliq, J. Zhong and K.M. Peng. 2016. Effect of boric acid supplementation on the expression of BDNF in African Ostrich chick brain. Biol. Trace Elem. Res. 170(1):208-315

25.Wang, J.; S.H.Li,G.M.Jin,C.F.Shang, H.L. Chen and Y.F.Gu.2007. Effect of drinking-boron on jejunum development of ani mal. Stud. Trace Elem. Health. 24(2):1-4.

26.Xiao, K., A. R. Ansari, Z. U. Rehman,H. Khaliq, H. Song, J.Tang, J. Wang, W. Wang, P. P. Sun, J. Zhong and K. M. Peng. 2015 .Effect of boric acid supplementation of ostrich water on the expression of Foxn1 in thymus. Histol. Histopathol. 30(11):1367-78.