

HEPATOTOXICOPATHOLOGY EVALUATION OF DIMETHYLFORMAMIDE (DMF) ON MALE ALBINO RATS LIVERS

H.Y. AL-Dleamy*

Researcher

Z. J.M. Jawad*

Asist. Prof.

* Dept. of Pathology and Poultry Disease, Coll. Vet. Medic. University of Baghdad, Iraq

*Corresponding Author: dr.hayder2388@gmail.com

ABSTRACT

This experiment was aimed to investigate the Toxicopathological effect of N, N-Dimethylformamide (DMF) (1/10LD₅₀) on the adult male rats' liver. Sixteen adult male rats were used in this experiment. After acclimatization for two weeks, they were divided equally into two groups as follows: Group-C-control: Normal diet and water for 30 days (n=8 rats). Group-T1: DMF 645.5mg/kg. B.W as 1/10LD₅₀ for 30 days (n=8rats), after thirty days collected blood for liver enzymes analysis then all animals killed at the end of the experiment and the liver samples saved at 10% formalin for histopathological preparation. The results showed that serum liver enzymes (ALP, ALT, and AST) concentrations of adult male rats after thirty days of oral DMF administration were significantly different (P<0.05) from the control group. Histopathological changes of group 1/10 LD₅₀ (T1) group appear enlargement of hepatocytes with mild degeneration and mild hyperplasia of kupffer cells, and focal infiltration of inflammatory cells mainly lymphocytes in the portal area and a large area of necrosis.

Keywords: dimethylformamide, hepatotoxicity, liver enzyme, serum, kupffer.

الدليمي و جواد

مجلة العلوم الزراعية العراقية - 2022: 53(5): 1123-1128

تقييم التأثير السمي المرضي لمادة ثنائي ميثيل فورماميد على اكباد ذكور الجرذان البيضاء

زينب جمال محمد جواد

حيدر يوسف الدليمي

استاذ مساعد

الباحث

قسم الامراض وامراض الدواجن, كلية الطب البيطري, جامعة بغداد

المستخلص

تهدف هذه التجربة الى دراسة التأثير السمي المرضي باستخدام 10/1 من الجرعة نصف القاتلة لمادة ثنائي ميثيل الفورماميد على كبد الجرذان البالغة. تم استخدام ستة DMF: من الذكور البالغة في التجربة. وبعد التأقلم لمدة اسبوعين للحيوانات , تم تقسيمهم بالتساوي إلى مجموعتين على النحو التالي: مجموعة السيطرة: غذاء طبيعي وماء لمدة 30 يوما (عدد = 8 جرذ) . مجموعة التجريب DMF : جرعت 645.5 ملغم/كغم من وزن الجسم 10/1 من الجرعة نصف القاتلة ولمدة 30 يوما (عدد = 8 جرذ). بعد ثلاثين يوما تم جمع الدم لتحليل إنزيمات الكبد ثم تم حفظ عينات الكبد لجميع الحيوانات المقتولة في نهاية التجربة في فورمالين بنسبة 10% للتحضير النسيجي. وأظهرت النتائج زيادة تراكيز إنزيمات الكبد (ALP ، ALT ، AST) في الحيوانات المعالجة بمادة DMF عن طريق الفم كانت مختلفة معنويًا (P < 0.05) عن مجموعة السيطرة. اما التغيرات النسيجية المرضية للمجموعة المعالجة ب 10/1 من الجرعة القاتلة للنصف اظهرت تنكس خفيف وتضخم للخلايا الكبدية مع زيادة طفيفة لخلايا كوفر، وارتشاح بؤري للخلايا الانتهابية واغلبها كان خلايا ليمفاوية في المنطقة البوابية للكبد ووجود منطقة كبيرة من النخر في مقطع اخر للكبد وتميز بنخر حول الوريد المركزي للفصيص الكبدي.

الكلمات المفتاحية: ثنائي ميثيل فورماميد، سمية الكبد، انزيمات الكبد، مصل، كوفر.

INTRODUCTION

Dimethylformamide (DMF) a major solvent predominantly used in the chemical industry and is a colorless to slightly yellow liquid with a faint amine-like odor. DMF has low volatility and can be miscible with water and the majority of organic liquids, and thus is globally used in a wide variety of industrial applications (12,27). DMF is mainly used in the production of inorganic chemicals, synthesized organic materials, pesticides, and leather, fabrics, plastics, and polyurethane materials (3). Also DMF used in pharmaceutical products (23). DMF is released into the environment as it enters various areas of the industry, affecting air quality as well as the health of humans and animals. China consumes the most DMF and produces roughly 45% of the world's DMF each year. China consumes two-thirds of the world's DMF (27). As the use of DMF has increased year after year, so has concern about its potentially toxic effects. DMF has been shown in animal experiments and epidemiological studies to be toxic to the liver, kidneys, and reproductive system in both humans and animals (7). Previous research has found that the severity of DMF-induced liver injury is directly related to exposure dosage, time of exposure, and the patient's liver function individuals exposed (17). Therefore, the toxicity of an industrial solvent could also differ depending on the experimental animals' species, age, strain, sex and route of administration (24). There have been previous reports of workers developing hepatic dysfunction as a result of DMF alone or in combination with other organic solvents (11). Hepatitis, fibrosis, cirrhosis, and cancer are among the liver toxicities caused by DMF (12). Because there have been few studies on DMF in Iraq, we designed this study to look into its potential toxicity in rats.

MATERIALS AND METHODS

Experimental design

Sixteen adult male rats were used in this experiment. After acclimatization for two weeks they were divided equally into two groups, First group control (C): Eight rats were orally distilled water daily for Thirty days. And the second group (T1): Eight rats were

received oral dose $1/10LD_{50}$ of DMF daily for thirty days.

Chemical

All chemicals purchase from (Alpha Chemika) India.

Preparation of DMF dose

The LD_{50} of DMF was estimation in rats using the Up and down method (1,2).

Experiment animals

Sixteen male Albino rats weighing 300-350 gm were used in the experiment. They ranged in age from 10 to 12 weeks. Animals were obtained from the University of Baghdad College of Veterinary Medicine - animal house, acclimatized to laboratory conditions, and housed in plastic cages for two weeks at ambient temperatures of $25^{\circ}C$ and 45-55 % relative humidity, with 12 hours of dark and light. Distilled water was used to treat the animals, according to Laboratory Animal Care Principles. To maintain a clean environment, bedding is changed every five days (5).

Blood collection

Blood samples were collected through cardiac puncture using disposable medical syringes (5 ml) at thirty days. The blood samples of each rat were stored in disposable tubes that were kept for no more than four hours before serum insulation. Samples were centrifuged for 15 minutes at a speed of 3000 rpm and then serum samples were placed in the freezer at $-18^{\circ}C$ before biochemical tests (18).

Biochemical Analysis

Activities of some enzymes and concentrations of certain biochemical parameters representing liver functions were determined in the rats blood as follows: Aspartate aminotransferase (AST), alanine aminotransferase (ALT), and Alkaline Phosphatase (ALP) activities were determined according to the method (15).

Histopathological Changes

Histological samples were taken from the animals after killing, and the liver was preserved in 10% formalin as a fixative to prepare histopathological sections after the thirty days from oral administration of DMF. The paraffin sections it thickness 3 - 4 μm were prepared and stained with hematoxylin and eosin (H and E) for histopathological examination under light microscopy (26).

Statistical analysis : Data of time recovery were analyzed as one way-ANOVA using the

GLM procedure of SPSS software version 22.00 (IBM SPSS Inc., Chicago, IL, USA). Means were separated using LSD at $P < 0.05$. Results presented as Mean \pm SEM. Individual animals were considered the experimental unit(8).

RESULTS AND DISCUSSION

Data in table 1 shows that serum liver enzymes (ALP, ALT, and AST) concentrations of adult

Table 1. Serum ALP, ALT, and AST concentrations (IU/L) of male rats treated orally DMF doses for 30days

Groups	AST	ALT	ALP
(1/10LD ₅₀)	114.12 \pm 3.02a	113.5 \pm 5a	492.5 \pm 13.627a
C	71.62 \pm 2.01b	62.25 \pm 2.63b	348.75 \pm 5.23b
LSD	8.021	12.810	33.912

Means with a different letter in the same column are significantly different ($P < 0.05$), T: male rats dosed orally 1/10 LD50 of DMF for 30days and C: control group dosed orally distilled water for 30 days, N=8

Histopathology results

Histopathological changes of group 1/10LD₅₀ (T1) group (Fig-1) showed enlargement of hepatocytes with mild degeneration and mild hyperplasia of kupffer cells, while focal infiltration of inflammatory cells mainly lymphocytes in the portal area and a large area of necrosis consist of MNCs mainly lymphocytes and there is RBCs also revealed respectively (Fig-2,3). Fig-4 shows a multifocal area of centrilobular necrosis. Mild degenerative change of hepatocytes, with focal aggregation of inflammatory cells around a congested blood vessel notes (Fig-5).

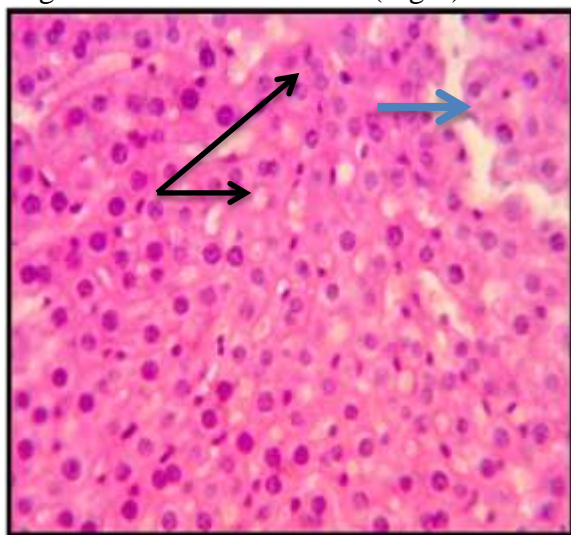


Figure 1. Histopathological section of liver of T1 group shows enlargement of hepatocytes with mild degeneration(Blue arrow) and mild hyperplasia of kupffer cells (Black arrow) (H&E stain 400X).

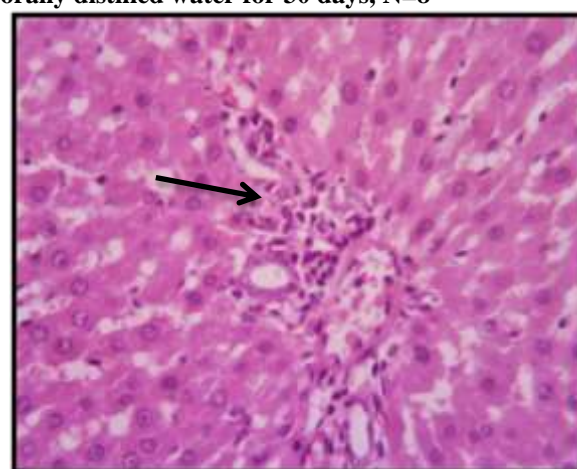


Figure 2. Histopathological section of liver of T1 group shows focal infiltration of inflammatory cells mainly lymphocytes in portal area(Black arrow) (H&E stain 400X).

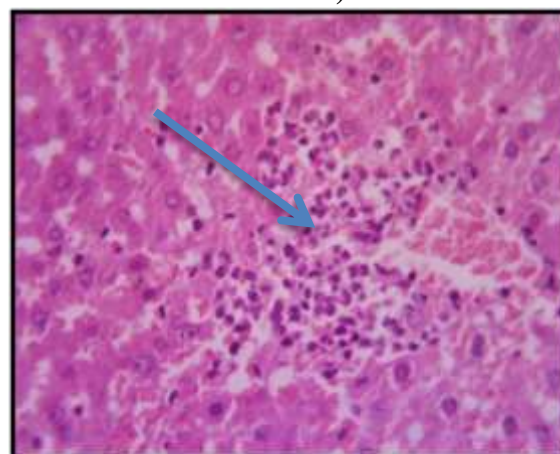


Figure 3. Histopathological section of liver of T1 group shows large area of necrosis consist of MNCs mainly lymphocytes and there is RBCs also(Blue arrow) (H&E stain 400X).

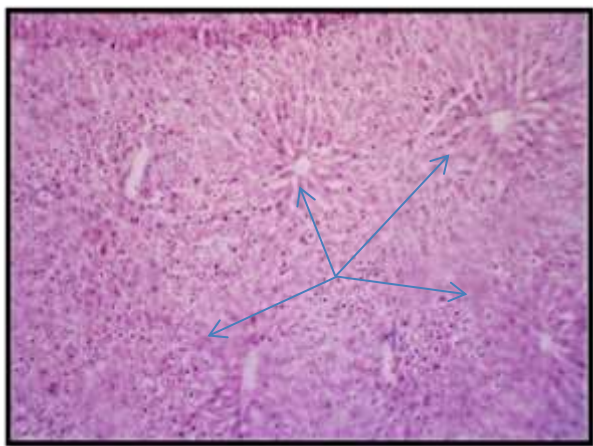


Figure. 4. Histopathological section of liver of T1 group shows multi focal area of centrilobular necrosis (BI

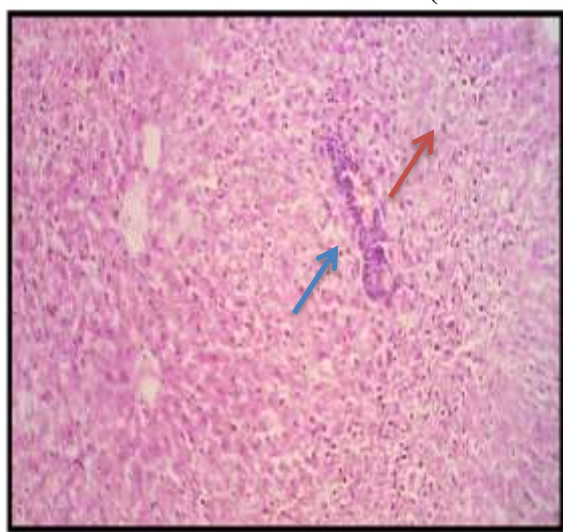


Figure. 5. Histopathological section of liver of T1 group mild degenerative change of hepatocytes (Red arrow) with focal aggregation of inflammatory cells around congested blood vessel (Blue arrow) (H&E stain 100X).

DMF is a toxic metabolite that is liberated in the liver after CYP2E1 metabolizes various endogenous and exogenous substrates to reactive metabolites, resulting in reactive oxygen species (ROS) (25). Several studies have shown that DMF can cause liver toxicity, which is characterized by an increase in the activities of serum liver enzymes such as AST, ALT, and ALP (6). DMF-induced liver damage was also demonstrated by an increase in serum enzymes. ALT, AST, and ALP are three important types of liver enzymes that are commonly used to assess hepatocyte damage. In the previous study, administration of DMF at concentrations of 0.32 g/kg, 0.63 g/kg, and 1.26 g/kg for 90 days resulted in increased

serum levels of ALT, AST, and ALP, indicating that DMF caused the liver injury (19). In a previous study it was shown that, after exposure to DMF, it leads to the production of reactive oxygen species that cause an increase in blood transaminases, such as AST, ALT and ALP which were useful indicators in assessing liver injury in workers who are professionally exposed to DMF (10). And histological changes such as necrosis and fibrosis (19). DMF is metabolized by cytochrome P450E1 to monomethyl and formamide derivatives like as N-hydroxymethyl-N-methylformamide (HMMF) (21). HMMF degrades thermolytic to form formaldehyde and N-methyl formamide (NMF). Because NMF is a potent hepatotoxicant in rodents, it is thought that this transformation is responsible for DMF's liver-damaging properties (16). In mice exposed to 1.26 g / kg DMF for 90 days, central hepatocyte enlargement of the liver exhibited massive hepatic swelling and perinuclear vacuoles with mild cell degeneration and fibrosis, as well as inflammatory cell infiltration (19).

An increase in the observed was observed in rats upon exposure centrilobular hepatocellular hypertrophy to DMF (14). At 50 mg/kg B.W. per day for 90-day dietary, mild effects on the liver (enlargement of hepatic cells) (9). The liver was the primary site of toxicity in rats and mice exposed to inhaled DMF for 13 weeks. Centrilobular hepatocellular necrosis seen in exposed rats was accompanied by increased activities of hepatic intracellular enzymes in the serum, and also by increases in relative liver weights. The centrilobular hepatocellular hypertrophy seen in exposed mice was accompanied by increased absolute and relative liver weights (13). DMF-induced death in rats was induced by significant centrilobular necrosis of the liver associated with hemorrhage and congestion for rats exposed to DMF from 2-wk to 13-wk at concentrations of 100-200-400-800 ppm for inhalation (22) Other studies have revealed that high exposure to DMF is responsible for biochemical and histopathological changes in the liver, including necrosis and disintegration of hepatocytes, as a result of oxidative stress caused by free radical production (10). DMF-

induced liver damage may reflect disturbance in liver cell metabolism, which results in distinctive changes in serum enzyme levels (4). Because they are cytoplasmic and are released into the circulation after cellular damage, ALT, AST, and ALP are the most sensitive signifiers used in the diagnostic test of hepatic damage (20).

CONCLUSIONS

Exposure to dimethylformamide should be considered one factor caused hepatitis and enhanced activities of hepatic enzymes in the circulation of injured liver by DMF of rats.

REFERENCES

- 1- Al-Rekabi F. M. K., A. Alsadawi and A. I. Al-ameedi 2021. A New approach in treatment acute ivermectin toxicity in male balb-C mice. *Iraqi Journal of Agricultural Sciences*. 52(2): 301–308
- 2- Al-Zuhairi A. H. 2020. Toxicological effects of aqueous extract of calotropis procera leaves in experimentally poisoned rabbits. *Iraqi Journal of Veterinary Medicine*. 44(1): 46–56
- 3- Antoniou E. E., H.-P. Gelbke, J. Ballach and M. P. Zeegers 2020. The influence of airborne N, N -dimethylformamide on liver toxicity measured in industry workers: A systematic review and meta-analysis . *Toxicology Research and Application*. 4 (1): 1-11
- 4- Das K. and A. K. Kathiriya 2012. Hepatoprotective activity of stevia rebaudiana bert. leaves against thioacetamide induced toxicity. *Turkish Journal of Pharmaceutical Sciences*. 9(3): 343–352.
- 5- Hafez E. 1970. Reproduction and breeding techniques for laboratory animals. Lea and Fibiger, Philadelphia: London.
- 6- Hamada M., M. Abe, Y. Tokumoto, T. Miyae, H. Murakami, Y. Hiasa, B. Matsuura, K. Sato and M. Onji 2009. Occupational liver injury due to N, N-dimethylformamide in the synthetics industry. *Intern. Med*. 48(18): 1647–1650
- 7- Hu Z. Y., J. Chang, F. F. Guo, H. Y. Deng, G. T. Pan, B. Y. Li and Z. L. Zhang 2020. The effects of dimethylformamide exposure on liver and kidney function in the elderly population: A cross-sectional study. *Medicine*. 99(27): e20749
- 8- IBM SPSS Statistics Software 2013. Version 22.0. SPSS Inc., Chicago, Illinois, U.S.A.
- 9- Kennedy G. L. and H. Sherman 1986. Acute and subchronic toxicity of dimethylformamide and dimethylacetamide following various routes of administration. *Drug Chem. Toxicol*. 9(2): 147-170
- 10- Kim K. W. and Y. H. Chung 2013. Hepatotoxicity in rats treated with dimethylformamide or toluene or both. *Toxicological Research*. 29(3): 187–193
- 11- Kim T. H., and S. G. Kim 2011. Clinical outcomes of occupational exposure to N, N -dimethylformamide : Perspectives from *Experimental Toxicology*. 2 (2): 97–104
- 12- Lei Y., S. Xiao, S. Chen, H. Zhang, H. Li and Y. Lu 2017. N, N-dimethylformamide-induced acute hepatic failure: A case report and literature review. *Experimental and Therapeutic Medicine*. 14(6): 5659–5663
- 13- Lynch D. W., M. E. Placke, R. L. Persing and M. J. Ryan 2003. Thirteen-week inhalation toxicity of N, N-dimethylformamide in F344/N rats and B6C3F1 mice. *Toxicological Sciences*. 72(2): 347–358
- 14- Malley L.A., T.W. Jr. Slone, C. Van Pelt, G.S. Elliott, P.E. Ross, J.C. Stadler and G. L. Jr. Kennedy 1994. Chronic toxicity/oncogenicity of dimethylformamide in rats and mice following inhalation exposure. *Fundam. Appl. Toxicol*. 23(2): 268–279
- 15- Mashi S. K. 2016. Effect of green tea extract on injured liver induced by acetaaminophen in rabbits adult male. *Iraqi Journal of Agricultural Sciences*. 47(6): 1549–1555
- 16- Mraz J., H. Cross, A. Gescher, MD. Threadgill and J. Flek 1989. Differences between rodents and humans in the metabolic toxification of N, N-dimethylformamide. *Toxicol Appl Pharmacol*. 98(3): 507-516
- 17- Nomiyama T., M. Uehara, H. Miyauchi, S. Imamiya, S. Tanaka and Y. Seki 2001. Causal relationship between a case of severe hepatic dysfunction and low exposure concentrations of N, N-dimethylformamide in the synthetics industry. *Industrial Health*. 39(1): 33–36
- 18- Nur A., J.B. Nusrat and U. Rafiq 2013. Review on in vivo and in vitro methods evaluation of antioxidant activity. *Saudi Pharmaceutical Journal*. 21(2):143-152

- 19- Rui D., C. Daojun and Y. Yongjian 2011. Liver and heart toxicity due to 90-day oral exposure of ICR mice to N, N-dimethylformamide. *Environmental Toxicology and Pharmacology*. 31(3): 357–363
- 20- Sallie R., J. Michael Tredger and R. Williams 1991. Drugs and the liver part 1: Testing liver function. *Biopharmaceutics & Drug Disposition*. 12(4): 251–259.
- 21- Scailteur V., E. Hoffmann, J. P. Buchet and R. Lauwerys 1984. Study on in vivo and in vitro metabolism of dimethylformamide in male and female rats. *Toxicology*. 29(3): 221-234
- 22- Senoh H., T. Katagiri, H. Arito, T. Nishizawa, K. Nagano, S. Yamamoto and T. Matsushima 2003. Toxicity due to 2- and 13-wk inhalation exposures of rats and mice to N, N-dimethylformamide. *Journal of Occupational Health*. 45(6): 365–375.
- 23- Syroeshkin A. V., T. V. Pleteneva, E. V. Uspenskaya, I. I. Saydinov, O. V. Levitskaya, T. E. Elizarova, M. A. Tribot-Laspierre and A. I. Odnovorov 2020. Ascorbic acid degradation in N, N-dimethylformamide solutions. *International Journal of Applied Pharmaceutics*. 12(2): 70–75
- 24- Tanaka K. I. 1971. Toxicity of dimethylformamide (DMF) to the young female rat. *Internationales Archiv Für Arbeitsmedizin*. 28(2): 95–105
- 25- Wang C., J. Yang, D. Lu, Y. Fan, M. Zhao and Z. Li 2016. Oxidative stress-related DNA damage and homologous recombination repairing induced by N,N-dimethylformamide. *Journal of Applied Toxicology*. 36(7): 936–945
- 26- Yassein S. N. 2020. Comparative study of pathogenicity between aspergillus fumigatus and penicillium chrysogenum in mice. *Iraqi Journal of Agricultural Sciences*. 51,168–175
- 27- Zhang Q., C. Huang, Y. Wei, Q. Zhu, W. Tian and C. Wang 2014. Risk assessment of N, N-dimethylformamide on residents living near synthetic leather factories. *Environ. Sci. Pollut. Res. Int*. 21(5): 3534-3539.