

## MOLECULAR DETECTION AND DERMATO PATHOLOGICAL ANALYSIS OF ORF VIRUS INFECTION IN SHEEP AND GOATS IN BASRAH PROVINCE

Y. J. Mohammed  
Lecturer

E. H. Yousif  
Assist Prof.

Dept. Patho. and Poult. Disease, Coll. Vet. Med, University of Basrah  
Dept. Patho. and Poult. Disease, Coll. Vet. Med, University of Baghdad  
Email: dr.yasmeenjasim@gmail.com

### ABSTRACT

This study was designed for the molecular diagnosis and assessment of histopathological changes of ORF infection in sheep and goats in Basra governorate in Iraq. The virus was detected by using -polymerase chain reaction. The samples were taken from the skin of the lips of animals infected with contiguous ecthema. Hundred samples taken from the sheep and 100 samples from goats of suspected animals, the results of the molecular diagnosis showed that 76 (76%) of sheep were infected and 71 (71%) of goats were infected by diagnosing the partial of *ORFV037* gene (173bp), and *ORFV039* (703bp), the sequences were determined and recorded in the NCBI and drawn the phylogenetic tree. The results of histopathological study showed presented various changes in cutaneous tissues in sheep include hyperplasia of hair follicles, sebaceous gland and sweet gland, parakeratosis, hyalinization of keratin Also to a picture of tumores, inflammation appear clearly in dermis also to hyperplasia of epidermis towered dermis. In goat showed proliferation of epidermis layer and papillae projection, Highly proliferation structures spinosum, sebaceous gland, sweet gland, and proliferation hair follicles with thickening it wall, hyperkeratosis of epidermis, infiltration of inflammatory cells and ulceration with necrotizing of epidermis.

**Keywords:** Molecular detection, dermato pathological, ORF virus in sheep and goats.

محمد ويوسف

مجلة العلوم الزراعية العراقية -2022: 53(3):611-624

التشخيص الجزيئي والأمراض الجلدية المتكونة من فيروس الاورف في الاغنام والماعز في محافظة البصرة

ايمان هاشم يوسف

ياسمين جاسم محمد

استاذ مساعد

مدرس

فرع الامراض وامراض الدواجن-كلية الطب البيطري-جامعة البصرة

فرع الامراض وامراض الدواجن-كلية الطب البيطري-جامعة بغداد

المستخلص

صممت هذه الدراسة للتشخيص الجزيئي وتقييم التغيرات المرضية النسيجية لمرض الاورف في الاغنام والماعز في محافظة البصرة في العراق، تم الكشف عن الفيروس باستخدام التقنيات الجزيئية وذلك باستخدام تقنية تفاعل البلمرة المستمر، تم اخذ عينات من جلد شفاه الحيوانات المصابة بالحميقاء الساري (الاورف). جمعت 100 عينة من الاغنام و 100 عينة من الماعز لحيوانات مشتبه بإصابتها بالمرض فأظهرت نتائج التشخيص الجزيئي اصابة 76 حيوان من الاغنام بنسبة (76%) و 71 من الماعز وبنسبة (71%) وذلك بتشخيص جزء من جين *ORFV037* والذي حجمه (173) قاعدة نيتروجينية وجين *ORFV039* بحجم (703) قاعدة نيتروجينية، تم تحديد تسلسل قواعد الجينات وتم تسجيل العينات في بنك الجينات ورسم الشجرة الوراثية لهم. أظهرت نتائج الدراسة النسيجية تغيرات مرضية نسيجية مختلفة في أنسجة جلد شفاه الاغنام تشمل فرط تنسج بصيلات الشعر، الغدد الزهمية والغدد العرقية، و *parakeratosis*، و *hyalinization* للكيراتين، وكذلك ظهور الأورام، ارتشاح الخلايا الالتهابية في الأدمة إضافة إلى فرط تنسج الأدمة اما بالنسبة للماعز. اظهرت النتائج وجود تكاثر خلايا البشرة، التنوعات الحلمية، وتكاثر الغدد الزهمية، والغدد العرقية، وبصيلات الشعر مع تثخن جدارها، وارتشاح الخلايا الالتهابية، إضافة إلى تنخر وتقرح خلايا البشرة.

الكلمات المفتاحية: التشخيص الجزيئي، الأمراض الجلدية، فيروس الاورف في الاغنام والماعز.

Received:20/3/2021, Accepted:23/5/2021

## INTRODUCTION

ORF is an acute, contagious, shrivel and economically significant zoonotic viral skin disease caused by ORF virus (ORFV) in sheep, goats and wild ruminants (9). ORF, an old rough English, typically affects the mucocutaneous junctions of the muzzle and lips, although gums, palate, and tongue may be affected by lesions particularly in lambs and children. Lesions on the eyelids, feet, and teats occur less frequently (28). ORF virus is a member of the poxviridae parapox virus community. The family has a length of around 260nm and a width of 160nm, consisting of a linear double-stranded DNA genome (134-139kbp) with a high GC content (63-64%) relative to other poxviruses (4). ORFV infection is usually referred to as ORF, infectious labial dermatitis, scabby mouth, contagious ecthyma, contagious pustular dermatitis, or sore mouth in sheep and goats (27). The disorder is also a very serious viral zoonotic infection related to debilitating non-systemic proliferative lesions (14). For people working with animal farmers, animal caregivers, veterinarians, it is more of an occupational risk (5). Transmission occurs by direct contact with an infected animal and/or with polluted ORF-containing fomites. Traditionally, through wounds or abrasions, the virus reaches the skin and creates the infection (13). In sheep and goats, the disease occurs mainly in young animals aged 3-6 months, while neonatal lambs and children aged 10-12 days may also be seriously affected (32). Older sheep, however, can also bear the virus without injury and put the disease into susceptible flocks (34). The infection have clinical characteristics differ, it may remain subclinical in some animals; however, case fatality may reach up to 80% occasionally and particularly in young animals (33). In goats and sheep, the typical advancement of ORF moves from erythema, through vesicle formation, to pustules, and then to scabs. Proliferative and sometimes lesions of the self-limiting on the skin of the lips, oral mucosa and around the nostrils are a characteristic of the disease. Lesions may also occur on the teats of nursing animals sometimes and rarely on other organs (41), lesions follow a well-defined pattern of

development: local erythema, followed by papule, vesicle, postulate, and scab formation. Scabs become dry and are shed as lesions heal, with no scar left on the site of the lesion (22). Infection prolongation and increased severity, are almost related to secondary bacterial infections. (25). The genome of the ORF virus encodes factors that either mimic host immunoregulatory proteins (37) or have reactive potential with host immune system components (8). The ORF virus encodes a gene for the protein inhibitory factor (GIF), that can bind and inhibit both ovine Interleukin-2 (IL-2) cytokines and the macrophage colony-stimulating factor of granulocytes (GM-CSF). No other poxviruses have found the GIF gene; it has been screened for preservation in other PPVs. (29). Post-mortem lesions of epidermal hyperplasia, ulcers were evident in semi-domesticated reindeer and hyperkeratosis, intra-epithelial pustules (40). At an early stage, acanthosis with pseudoepitheliomatous hyperplasia, superficial multiloculated vesicles, superficial multiloculated vesicles and pustules is found to form ballooning degeneration of vesicles or pustules (23), accompanied by granulomatous and papillomatous characteristics (31). Negative stain electron microscopy of scabs of infected animals achieves laboratory diagnosis of the disease (15). Fluorescent Antibody Technique (IFAT), Agar Gel Immunodiffusion (AGID), Virus Neutralization Test (VNT) and Enzyme Linked Immunosorbent Assay (ELISA) (17,39) are several serological tests used for diagnosis of ORF virus. The development of the methods of PCR for the DNA detection met the criteria for precise and responsive laboratory diagnosis of the disease (15,35).

## MATERIALS AND METHODS

**Sample collection:** This method was carried out according to the guidelines (2,42). Different cases of sheep and goats were clinically diagnosed in different areas of the provinces of Basrah, samples were taken from sheep and goats infected with ORF (100 sample for each) between December 2019 and December 2020 from the province of Al-Basrah, the animals suffering from proliferative skin lesions especially at lips and commissures severe proliferative dermatitis, lesions eventually develop into thick, brown,

rapidly growing scabs over areas of granulation, inflammation and ulceration (papules, pustules and vesicles) on the lips, commissures in young sheep and goat flocks at Basrah province. Samples were collected on 50% glycerin and 50% buffer saline from affected skin lesion from sheep, and goats from different ages from both males and female with no history of vaccination against ORF virus. The tissues samples stored at -20°C until used for DNA extraction. For histopathological examination skin lips biopsies collected from infected animals through standard techniques.

**Molecular study:** Extraction of DNA, animal samples (mouth and lip scabs and biopsy samples) were obtained for genomic DNA extraction using the DNA Mini Kit (QIAGEN). Dried lamb and goat scabs (250mg of homogenized tissue) were collected from different farms in Basrah province and put in a 2ml micro centrifuge tube containing 50% PBS and 50% glycerin and stored at refrigerated temperatures before arrival at the laboratory and stored before processing at -20°C. Tissues were centrifuged at 14,000rpm for 10min. Then taken 500µl of viral supernatant for DNA extraction. The concentration of extracted DNA was determined by NanoDrop spectrophotometer at 260nm and 280nm and stored at -20°C.

**Polymerase Chain Reaction (PCR):** DNA was amplified by performing PCR technique using (Go Taq Green Master mix (M7822), Promega/USA) following the manufactures instructions. Two primer pairs were designed to identify important ORF virus including confirmed ORF virus primer, which is amplicon size (173bp) part of *ORFV037* gene (F2: 5'- CCAGGGGAAGTTCAGGTACG -3' and R2: 5'- ACTACGAACTGTGGGCGAG -3') and ORF virus amplicon size (703bp) most of *ORFV039* gene (F1: 5'- CACCTCGTTGCGGAAGTAGT -3' and R1: 5'-ATGTCATGGGCGGTTGAGTT-3'). While the amount used in the PCR reaction mixture was done according the standard application Go Taq® G2 Green Master Mix, Promega, USA by added 25µl Go Taq® G2 Green Master Mix, 2µl upstream primer 10µM, 2µl downstream primer 10µM, 3µl DNA template and nuclease-free water up to 50µl (18µl). The

mixture was briefly spine and placed in the thermal cyclor. The annealing temperature for amplicon size (173bp) primer was 56°C, while amplicon size (703bp) primer was 57°C. The PCR product was then detected on agarose gel stained with ethidium bromide, used 100bp DNA ladder, Promega, USA. The PCR conditions for this study can be clarified: 5min for initial denaturation at 95°C. followed by 95°C for 45sec, (56-57)°C for 45sec and 72°C for 45sec, all this steps returned 35 cycles of. Then held the reaction for 6min at 72°C, and then 5min 4°C cooled down the reaction. Then detected the product of PCR on agarose gel which stained by ethidium bromide, Then 100bp DNA ladder used, Promega, USA.

**DNA sequencing and sequences analysis:** Then sent product of PCR for sequencing to Macrogen (Korea) company. The sequences were edited and aligned by using evolutionary analyses were conducted in MEGA7. The results contrasted with data from gene bank gained and published which is available at the NCBI online.

**Histopathological study:** Skin biopsies were taking by used sterilized scissors and forceps and fixative in formalin 10% after that performed standard procedures for histopathological diagnosis specimens from infected sheep and goat mouth skin. Within the Veterinary college's, pathology department, the slides were prepared and analyzed. The colored slides of Hematoxylin and Eosin (HE) were used to identify the histological characteristics of skin infection by optical microscope Olympus according to Luna (25,1).

## **RESULTS AND DISCUSSION**

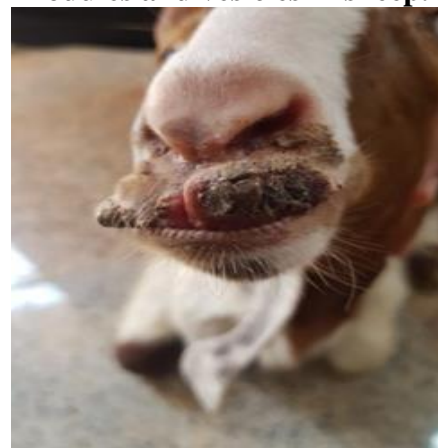
ORF, also known as infectious ecthyma in sheep and goats, is a serious viral disease. It is often considered to be a benign disease, but a malignant type has been identified in a few places around the world. ORF virus (ORFV) is a member of the family Poxviridae's genus Parapoxvirus (PPV) (12). Contagious ecthyma (CE) is a serious exanthematic dermatitis that affects both domestic and wild small ruminants (33). Direct contact with the virus causes infection, which is highly immune and can persist in the environment for more than a year. Furthermore, the disease is most common in young sheep, although it is

sometimes seen in older sheep that graze on rough pastures with cut stalks of cereal plants, which may predispose to infection with scabby mouth because oral abrasions improve the virus's ability to gain entry (6). The present study was conducted to study the ORF disease in Basrah province in sheep and goats, the disease was diagnosed based on clinical signs, molecular identification and invention histopathological lesions. In both sheep and goats, clinical examination revealed typical ORF disease lesions that began as viscales, papules, and pustules, and present scraps on the region of ulceration in the lips and mouth, as well as around the commeasure and less in other sections (figures 1,2). Disorders resulting from skin damage such as necrosis and ulceration of the epidermis and the dermis could be due to a cellular response. Increasing the delayed sensitivity and infiltration of inflammatory cells is the cutaneous response to infection, all that agreed with Diallo (10), whom explain the typical lesion of ORF virus infection in sheep and goats include viscales, papules, pustules and scab formation in skin of lips, inside and around mouth and commeasure. The findings of present study agree with Mondal et al, those a researcher found a variable degree of gross lesions such as viscales, papules, and wart-like lesions on infected animals' lips and around their mouths, but not on the rest of their bodies (30). This is because of the closeness of animals to confinement and grazing, which cause small abrasions on the mouth and lips of the animal during feeding and viral interactions through abrasions or skin injuries and the replication of epidermal keratinocyte regeneration. inaddition present clinical lesion started by skin lesion of mouth and lips as nodules and vesicles showed in figures (1,2). Molecular identification by PCR assay from total of 100 isolate samples from sheep and looks like from goats suffering of suspected ORF. According to the results out of the 200 tested skin lips samples of both sheep and goats; 76 samples out of 100 tested (76%) from sheep and 71 samples out of 100 tested (71%) of goats (Table 1). The result of current study of sheep draw near to the result of Karim in Al-Qadisiya in detection of sheep ORF, the percentage was 74.6% of morbidity rate of

animal from 1-6 month (20), as well as the morbidity rates up to 70% and sometime increased rates up to 90% had been reported in lambs after secondary bacterial infection (38). Present search results differed greatly when compared with Jae-Ku (18), the rate of ORF infected goat are 15%, The big difference is due to the fact that the researchers took random samples from the field from the goats, which numbered 400 animals, and the animals were randomly, from this sample which only 60 samples are infected. The incidence was approaching 60% of infected goats by ORF, this result similar to Keshan (21). The results of our research approximated the rate of infection in goats, and the slight difference in the ratios could be attributed to the different breeding conditions, weather and health conditions between Iraq and China. Figure (3) represented the site of ORF virus amplicon size  $\approx 173$ bp part of *ORFV037* gene on the left of the figure and ORF virus amplicon size  $\approx 703$ bp most of *ORFV039* gene on the right.



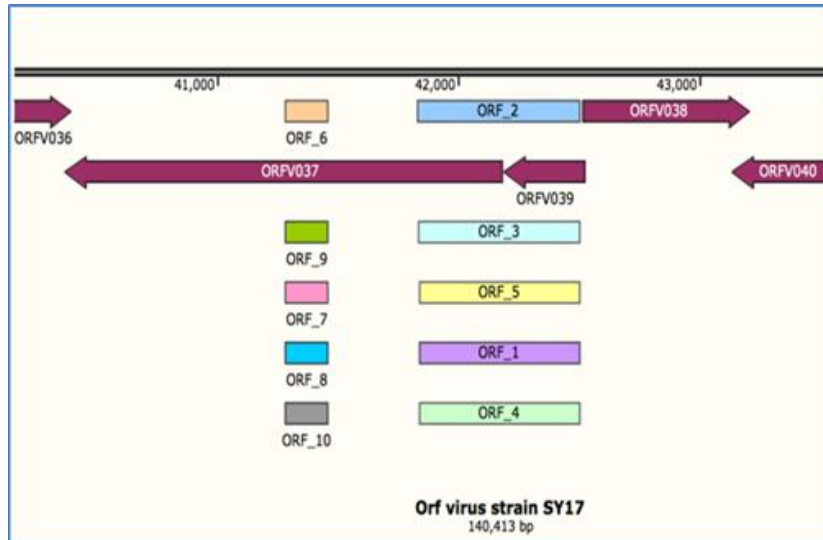
**Figure 1. Skin lesion of mouth and lips as nodules and vesicles in sheep.**



**Figure 2. Skin lesion of mouth and lips as nodules and vesicles in goat.**

**Table 1. Number and percentage of infected samples isolated from skin lips of sheep and goats**

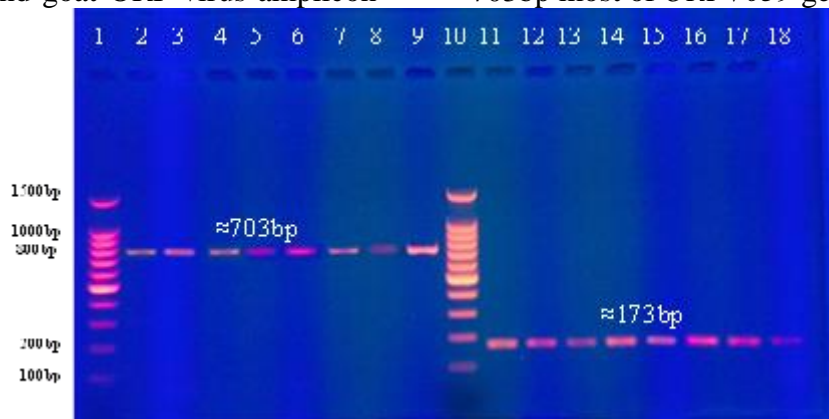
No. of Samples	Animal	No. of Samples	No. of Infected samples	%
200	Sheep	100	76	76
	Goat	100	71	71
	Both	200	147	73.5



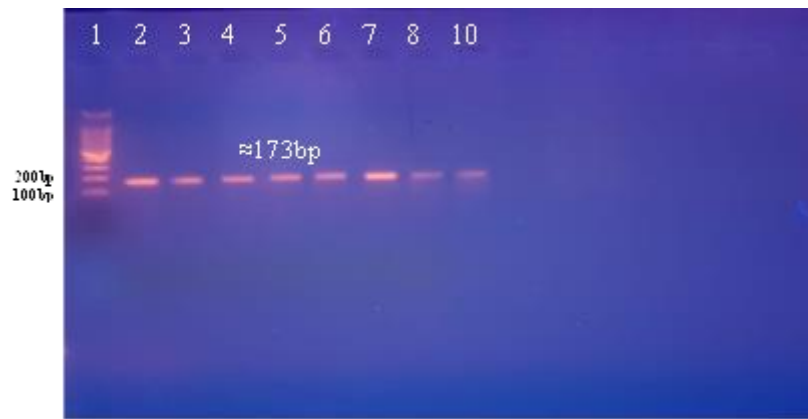
**Figure 3. Site of ORF virus amplicon size ≈173bp part of *ORFV037* gene on the left of the figure and ORF virus amplicon size ≈703bp most of *ORFV039* on the right**

The PCR used for confirmed and detected ORF virus with both genes gave the same results. Figure (4) represented the gel electrophoresis of PCR-amplified of goats ORF virus amplicon size ≈173bp part of *ORFV037* gene and goat ORF virus amplicon


size ≈703bp most of *ORFV039* gene, while figures (5,6) represented the gel electrophoresis of PCR-amplified sheep ORF virus amplicon size ≈173bp part of *ORFV037* gene and sheep ORF virus amplicon size ≈703bp most of *ORFV039* gene respectively.



**Figure 4. Gel electrophoresis of PCR-amplified of goats ORF virus, lines 1 and 10 are DNA ladders, lines (2 to 9): goats ORF virus amplicon size ≈703bp most of *ORFV039* gene. Amplicon size ≈173bp part of *ORFV037* gene in lanes (11 to 18).**



**Figure 5. Gel electrophoresis of PCR-amplified sheep ORF virus amplicon size  $\approx 173$ bp part of *ORFV037* gene.**



**Figure 6. Gel electrophoresis of PCR-amplified sheep ORF virus amplicon size  $\approx 703$ bp most of *ORFV039* gene**

Phylogenetic tree of five of *ORFV037* gene samples of ORF virus between them shown in (figure 7), as well as phylogenetic tree five of *ORFV039* gene samples of ORF virus between them shown in (figure 8). Figure 9 represented the phylogenetic tree of ten samples of ORF virus between them, five of them of *ORFV037* gene (ORF\_YEO 1-5) and five of *ORFV039* gene (ORF\_YEO 6-10). For all figures (7,8,9) showed the evolutionary relationships of sequences of ORF virus strains of both sheep and goats of *ORFV037* and *ORFV039* gene, the introductory consensus tree inferred from 500 replicates is taken to represent the evolutionary history of the analyzed taxa (11). Branches corresponding to the cloned partitions are folded in less than 50% of the bootstrap copies. The percentage of duplicate trees in which related taxa clustered together in a bootstrap test (500 replicates) is shown next to the branches (11). Then, the evolutionary distances were calculated using the Poisson correction method (43) and the number of amino acid substitutions for each site. These evolutionary analyzes were

performed on a program, MEGA7 (24). Phylogenetic tree of five *ORFV037* gene samples ORF virus with NCBI isolate represented in figure 10, as well as phylogenetic tree five of *ORFV039* gene samples of ORF virus with NCBI isolate represented in figure 11. Figure 12 represented phylogenetic tree of ten samples of ORF virus with NCBI isolate, five of them of *ORFV037* gene (ORF\_YEO 1-5) and five of *ORFV039* gene (ORF\_YEO 6-10). These three figures (10,11,12) showed the evolutionary relationships of ORF strains (YE06-YE10). The evolutionary history was inferred using the Neighbor-Joining method (35). An introductory consensus tree is then taken from 500 replicates to represent the evolutionary history of the analyzed taxa (11). Then the branches corresponding to the cloned partitions are folded in less than 50% of the bootstrap copies. Also, the percentage of duplicate trees in which related classes cluster together in the bootstrap test (500 replicates) is displayed next to the branches (11). Evolutionary distances were also calculated

using the Jukes-Cantor method (19), it is in units of the number of basic alternatives for each site. 5 nucleotide sequences were included in the analysis. Codon positions included were first + second + third + non-

coding. Then all positions with gaps and missing data were eliminated. Finally, there were a total of 446 jobs in the final data set. These phylogenetic analyzes were performed within a program called MEGA7 (24).

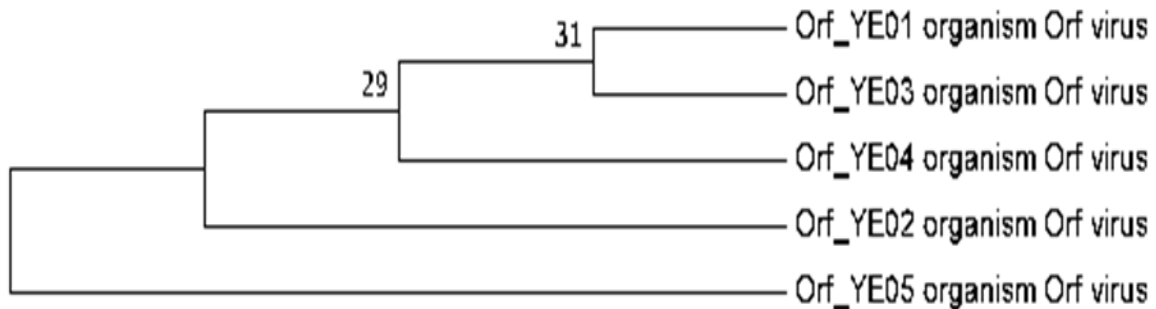


Figure 7. Phylogenetic tree of five of *ORFV037* gene samples of ORF virus between them

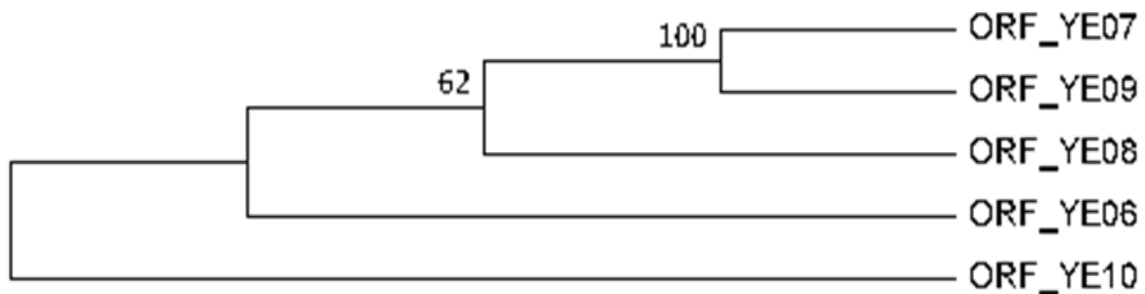


Figure 8. Phylogenetic tree of five of *ORFV039* gene samples ORF virus between them.

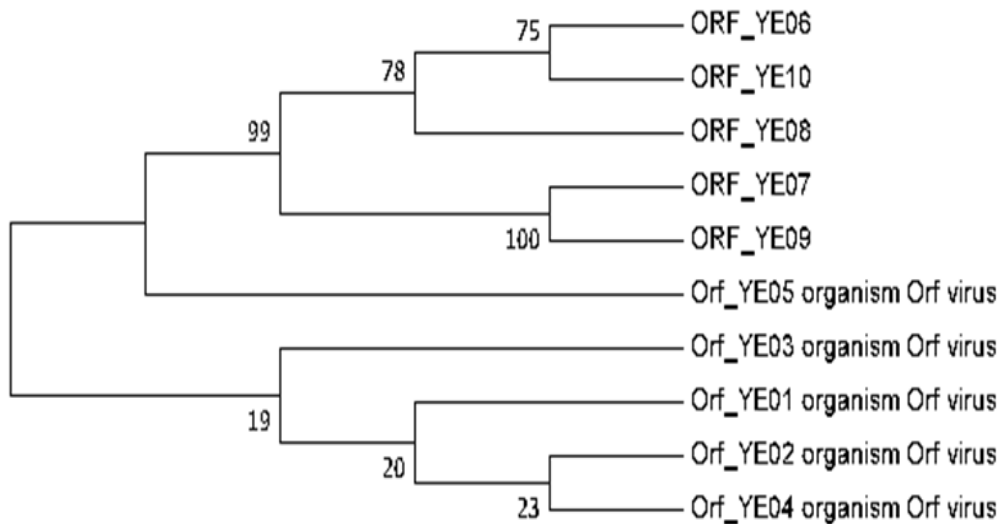


Figure 9. Phylogenetic tree of ten samples of ORF virus between them, five of them of *ORFV037* gene (ORF\_YEO 1-5) and five of *ORFV039* gene (ORF\_YEO 6-10).

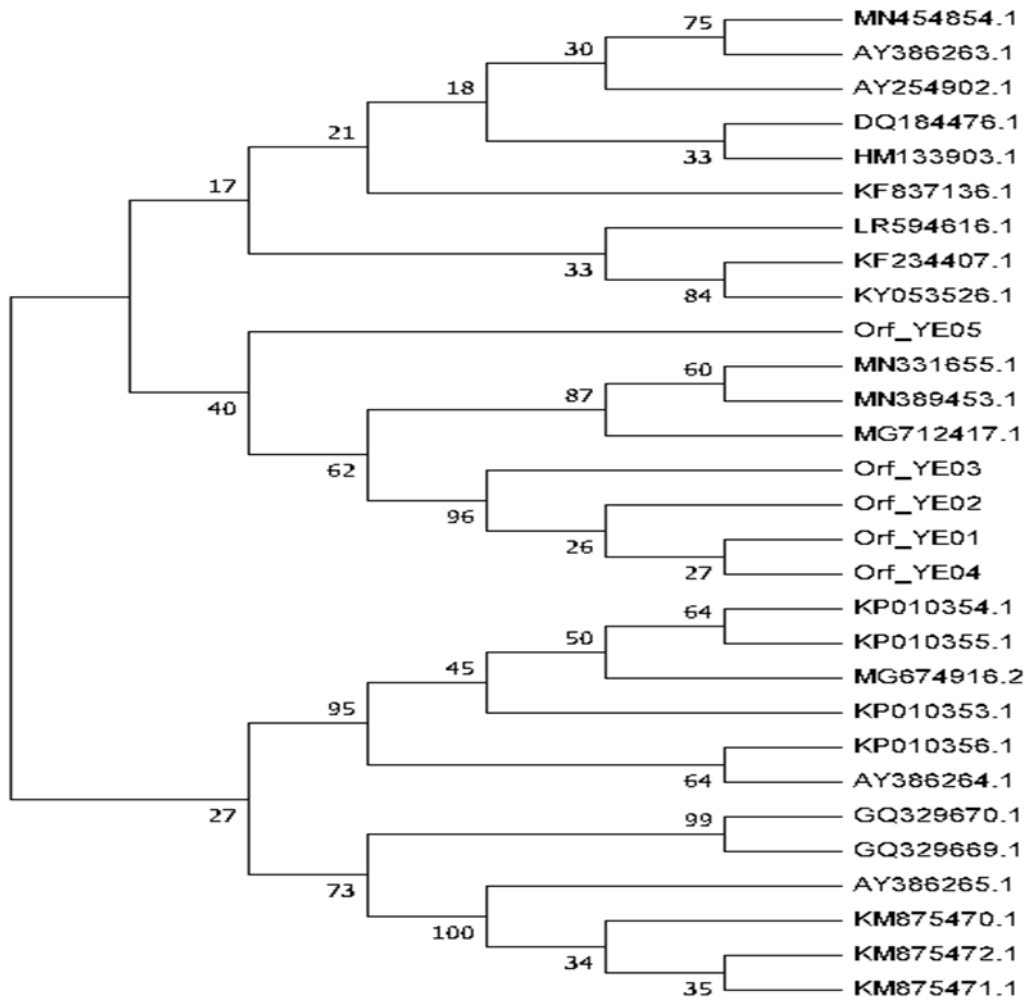


Figure 10. Phylogenetic tree of five of *ORFV037* gene samples ORF virus with NCBI isolate

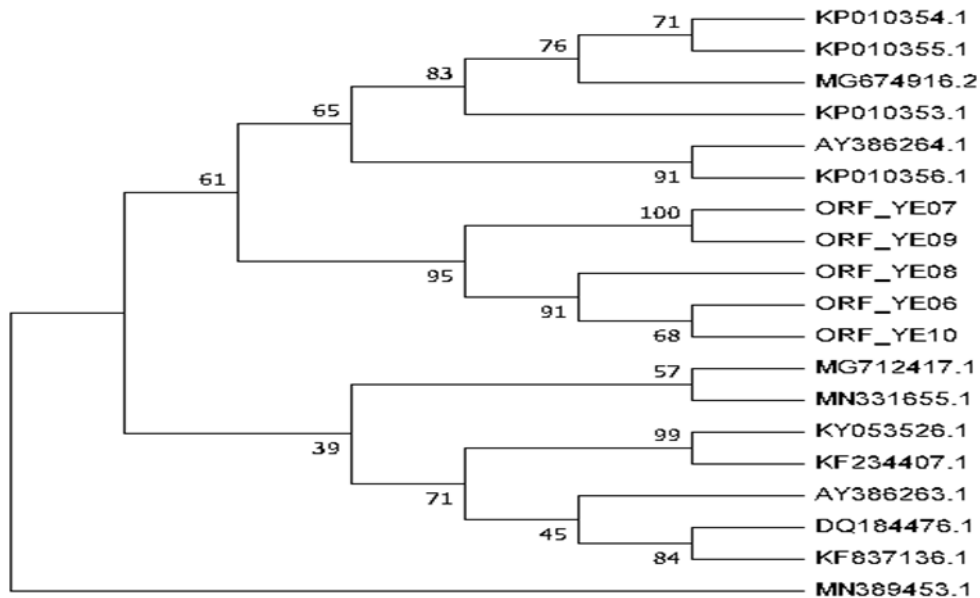


Figure 11. Phylogenetic tree of five of *ORFV039* gene samples ORF virus with NCBI isolate



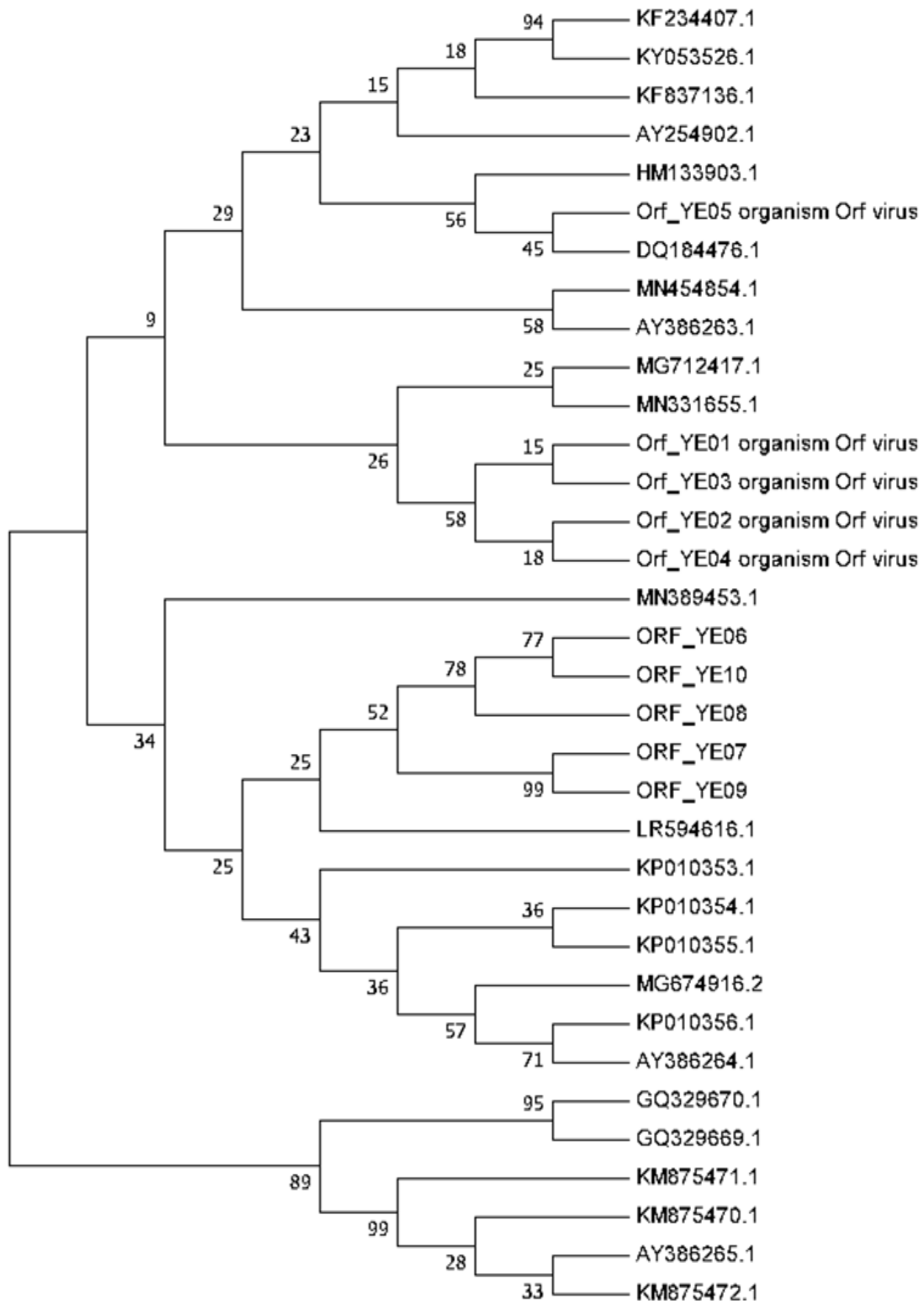
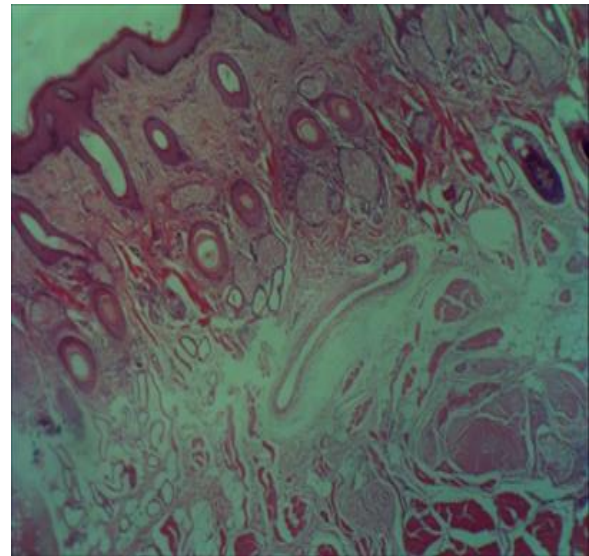
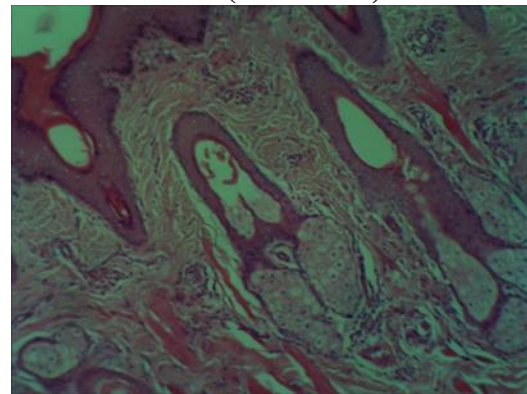


Figure 12. Phylogenetic tree of ten samples of ORF virus with NCBI isolate, five of them of *ORFV037* gene (ORF\_YEO 1-5) and five of *ORFV039* gene (ORF\_YEO 6-10).

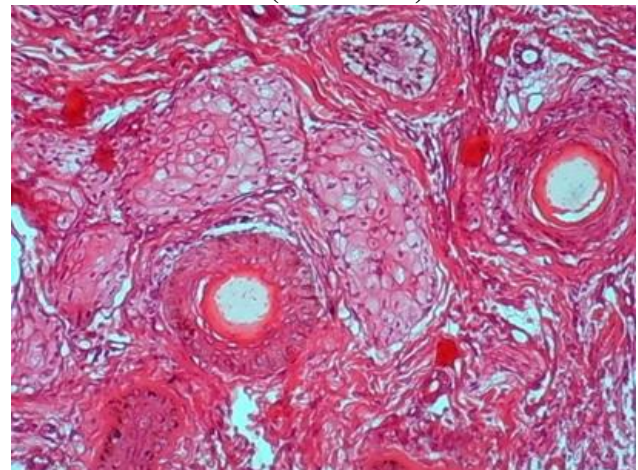
The result of histopathological examination showed normal structure of lips skin section of group of control which manifested by normal histological structure in figures (13,14). Our result showed presented various changes in sheep cutaneous tissues include hyperplasia of hair follicles, sebaceous gland and sweat gland (figure 15), parakeratosis in addition for hyalinization of keratin and epidermis enclosed many islets of dermis (figure 16). Other changes comprise a picture of tumors which consist of proliferating basophilic (hyperchromatic) cells towards islets of dermis in addition to proliferation skin adnexa and the inflammation appear clearly in dermis (figure 17), also to hyperplasia of epidermis towered dermis with papillae projection represented in (figure 18), these changes may be as result from inflammatory and cellular response against to virus infection that show immune response play a key role defense mechanism to ORF virus infection. These result agreed with de la Concha-Bermejillo et al and Karim (7,20), they observed present hyperplasia in basal layer, hyperplasia of hair follicles, sebaceous gland and sweat gland also present hyperkeratosis on epidermis, increase hyperplastic cells of stratum, layer eosinophilic cytoplasmic inclusion bodies in swollen cells and thickening wall hair follicles. As well as the result of present study in goat showed proliferation of epidermis layer and papilli projection outer and enter skin layers that protrusion in dermis forming many structures of skin (figure 19). Highly proliferation structures spinosum, sebaceous gland, sweat gland, and proliferation hair follicles with thickening it wall (figure 20), hyperkeratosis (figure 21), infiltration of inflammatory cells and ulceration with necrotizing of epidermis represented in (figure 22), these lesions may be due to skin response to this type of viruses (epitheliotropic virus) and immune variation of the infected animals, the reasons of this result because of the virus following the skin damage, the virus is not institutionalized in the epidermis, but deployed in the injured epidermis and deeply to dermis. The result of current study match to result of Buddle and Pulford in histopathological changes (3).



**Figure 13. Normal structure of sheep lips skin. (H&E X10).**



**Figure 14. Normal structure of goat lips skin. (H&E X40).**



**Figure 15. Hyperplasia of hair follicles, sebaceous gland and sweat gland. (H&E X40).**

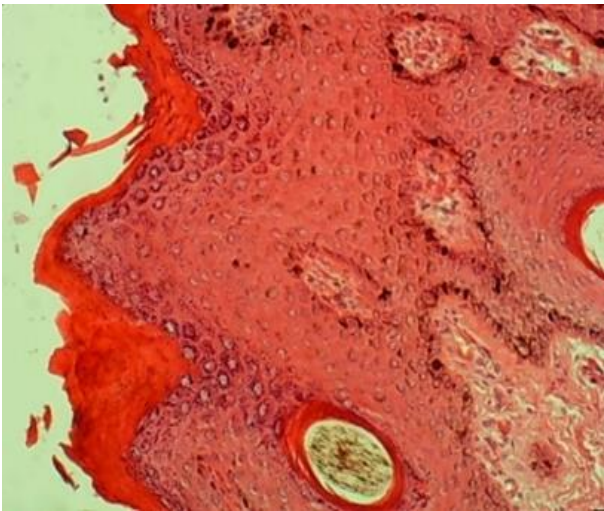


Figure 16. show epidermal parakeratosis and hyalinization(white arrow) with epidermis enclosed many islets of dermis (pink arrow). (H&E X40).

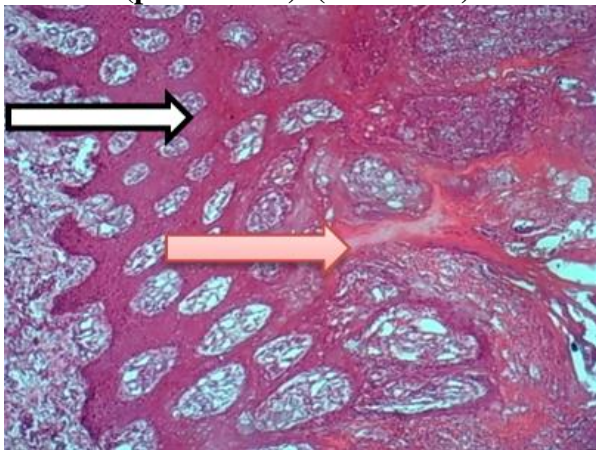


Figure 17. A picture of tumores which consist of proliferating basophilic (hyperchromatic) cells towards islets of dermis, proliferation skin adnexa (white arrow) and the inflammation appear clearly in dermis (pink arrow). (H&E X10).

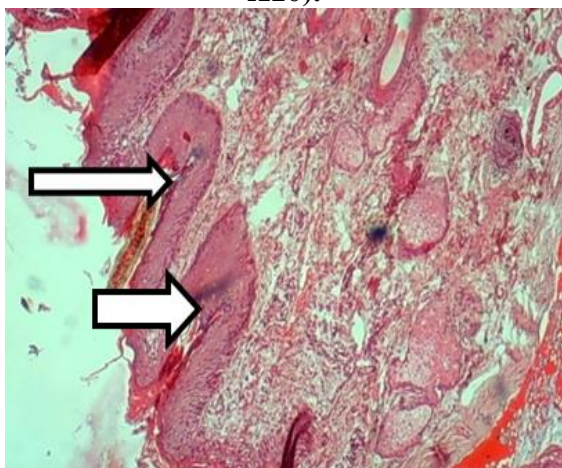


Figure 18. hyperplasia of epidermis towered dermis with papillae projection (white arrow). (H&E X10).

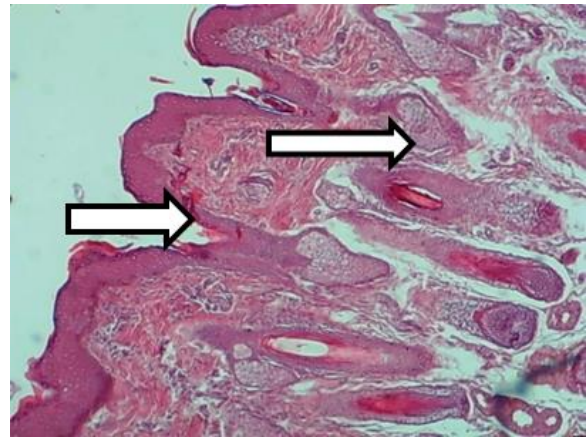


Figure 19. Proliferation of epidermis layer and papilli projection out and enter the layers skin that protrusion in dermis foaming many stracture of skin (white arrow). (H&E X10).

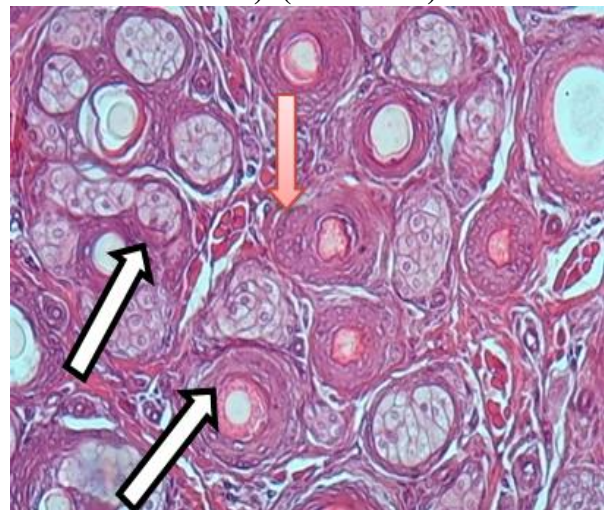


Figure 20. Highly proliferation structures spinosum, sebaceous gland, sweat gland, and proliferation hair follicles (white arrow) with thickening it wall (pink arrow). (H&E 10X).

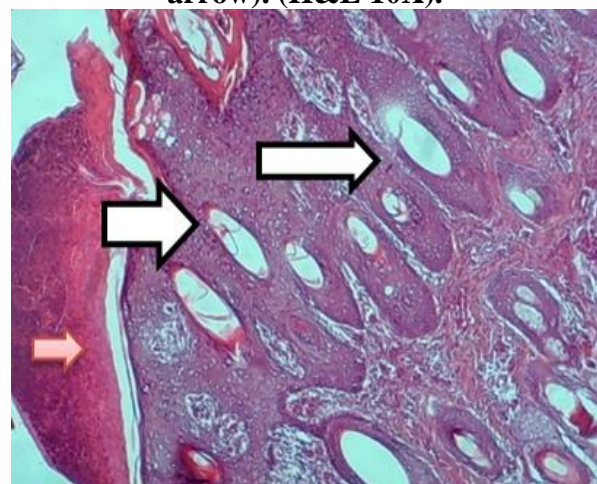
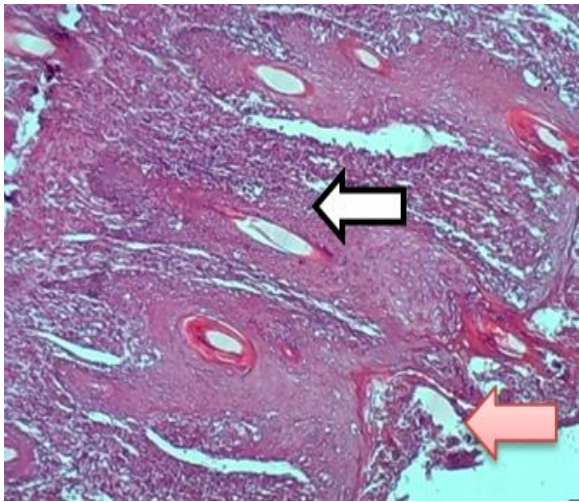


Figure 21. Proliferation of hair follicles (white arrow) and epidermal hyperkeratosis (pink arrow). (H&E X40).



**Figure 22. Proliferation of hair follicle with infiltration of inflammatory cells (white arrow), ulceration with necrotizing of epidermis (pink arrow). (H&E X40).**

#### REFERENCES

1. Abbas, A.A. M.K. Faraj, and A.R. Abed. 2012. Some biochemical and histopathological effects of different oral doses Ochratoxin A in male rats. Proceeding of the Eleventh Veterinary Scientific Conference., The Iraqi Journal of Veterinary Medicine., 36, special issue (2): 182-189
2. Ali, M.H. M.H. Ahmed, S.M. Tamam, A. Arafa, and A. Saad. 2013. Molecular Characterization of ORF Virus Isolated from Sheep and Goats in Egypt. *Global Veterinaria* 11: 98-106
3. Buddle, B. and H. Pulford. 1984. Effect of passively-acquired antibodies and vaccination on the immune response to contagious ecthyma virus, *Veterinary Microbiology*, 9, 515-552
4. Chan, K.W. C.H. Yang, J.W. Lin, H.C. Wang, F.Y. Lin, and S.T. Kuo. 2009. Phylogenetic analysis of parapoxviruses and the C-terminal heterogeneity of viral ATPase proteins. *Gene.*; 432:44-53
5. Charalambos, B. S.M. Vasia, S. Vasiliki, C. George, and B. Fthenakis1 2012. Phylogenetic analysis of strains of ORF virus isolated from two outbreaks of the disease in sheep in Greece, *Virology Journal*, 9:24. <http://www.virologyj.com/content/9/1/24>
6. Constable, P.D. K.W. Hincheliff, S.H. Done, and W. Grunberg. 2017. *Veterinary Medicine. A textbook of the disease of cattle, sheep, goats and horses* 911<sup>th</sup> edn), WB Saunders Co. pp. 1593-1596
7. de la Concha-Bermejillo, A. Z. Guo, J. Zahang, and D. Waldron. 2003. Severe persistent ORF in young goats. *J Vet Diagn Invest*, 15:423-431
8. Deane, D. C.J. McInnes, A. Percival, A. Wood, J. Thomson, A. Lear, J. Gilray, S. Fleming, A. Mercer, and D. Haig. 2000. ORF virus encodes a novel secreted protein inhibitor of granulocytemacrophage colony-stimulating factor and interleukin-2. *J. Virol.* 74, 1313-1320
9. Delhon, G. E.R. Tulman, C.L. Afonso, and Z. Lu, 2004. Concha-Bermejillo A, Lehmkuhl HD, et al. Genomes of the parapoxviruses ORF virus and bovine papular stomatitis virus. *J Virol.*;78:168-177
10. Diallo, A. and B.J. Viljoen. 2007. Genus capripoxvirus. In *Poxviruses*, pp: 167-181. Birkhäuser Basel
11. Felsenstein, J. 1985. Confidence limits on phylogenies: An approach using the bootstrap. *Evolution* 39:783-791
12. Fleming, S.B. and A.A. Mercer. 2007, Genus Parapoxvirus, in *Poxviruses. Birkhauser Advances in Infectious Diseases*, A. A. Mercer, A. Schmidt, and O. Weber, Eds., pp. 127–165, Birkhauser “ Basel
13. Fleming, S.B. L.M. Wise, and A.A. Mercer, 2015. Molecular genetic analysis of ORF virus: a poxvirus that has adapted to skin. *Viruses.*;7(3):1505-139
14. Gao, Y. Y. Zhao, J. Liu, M. Zhou, H. Liu, F. Liu, W. Yang, and D. Chen. 2016. ORF in goats in China: prevalence and risk factors. *J Agric Sci Technol A.*;6:116-123
15. Guo, J. J. Rasmussen, A. Wünschmann, and A. de La Concha-Bermejillo. 2004. Genetic characterization of ORF viruses isolated from various ruminant species of a zoo. *Vet Microbiol* 99: 81-92
16. Inoshima, Y. K. Murakami, T. Yokoyama, and H. Sentsui. 2001. Genetic heterogeneity among parapoxviruses isolated from sheep, cattle and Japanese serows (*Capricornis crispus*). *J Gen Virol* 82: 1215-1220
17. Inoshima, Y. S. Shimizu, N. Minamoto, K. Hirai, and H. Sentsui. 1999. Use of protein AG in an enzyme-linked immunosorbent assay for screening for antibodies against parapoxvirus in wild animals in Japan. *Clin Diagn Lab Immunol* 6: 388- 391

18. Jae-ku, O. R. In-Soon, L. Kyung-Hyun, L. Kyoung-Ki, K. Hye-Ryoung, J. Young-Hwa, and L. O-Soo. 2009. Phylogenetic analysis and characterization of Korean ORF virus from dairy goats: case reported. *Virology Journal*, 6:167
19. Jukes, T.H. and C.R. Cantor. 1969. Evolution of Protein Molecules. In Munro HN, editor, *Mammalian Protein Metabolism*, pp. 21-132, Academic Press, New York
20. Karim, S.M. 2015. Study of some clinical and epidemiological features and rapid detection of ORF diseases in sheep by molecular techniques. A thesis of master science in Veterinary Medicine, Al-Qadisia University. Pp; 96-98
21. Keshan, Z. L. Zhongxin, S. Youjun, Z. Haixue, J. Ye, H. Jujun, and L. Xiangtao. 2010. Diagnosis and phylogenetic analysis of ORF virus from goats in china: a case report. *Virology Journal*, 7:78
22. Kinley, G.E. C.W. Schmitt, and J. Stephens-devalle. 2013. Case report A case of contagious Ecthyma ( ORF Virus ) in a nonmanipulated laboratory Dorset Sheep ( *Ovis aries*), 2013.Article ID 210854, 5 pages; 2013
23. Kluge, J.P. N.F. Cheville, and T.M. Peery. 1972. Ultrastructural studies of contagious ecthyma in sheep. *Am. J. Vet. Res.* 33:1191-1200
24. Kumar, S. G. Stecher, and K. Tamura. 2016. MEGA7: Molecular Evolutionary Genetics Analysis version 7.0 for bigger datasets. *Molecular Biology and Evolution* 33:1870-1874
25. Lewis, C. 1996. Update on ORF. In *Farm Animal Practice*, 18: 376-381
26. Luna, L.G. 1968. Manual of histologic staining methods of armed forces institute of pathology. 3rd edition. McGraw-Hill book company. cited by Ibrahim MK. *Histopathological and Histochemical Changes of Small Intestine Infected with Giardiasis in Human and Experimental Model*. PhD thesis. Biology department. Basrah University. 2004, pp:26. doi.org/10.29079/vol14iss2art349
27. MacLachlan, N.J. and E.J. Dubovi. 2011. Poxviridae. In: *Fenner's Veterinary Virology*. 4th ed. London: Academic. Pp: 151-165
28. Maclachlan, N.J. and E.J. Dubovi. 2017. *Fenner's Veterinary Virology*. 4 ed. Elsevier
29. McInnes, C.J. D. Deane, D. Haig, A. Percival, J. Thomson, and A.R. Wood. 2005. Glycosylation, disulfide bond formation, and the presence of a WSXWS-like motif in the ORF virus GIF protein are critical for maintaining the integrity of Binding to ovine granulocytemacrophage colony-stimulating factor and interleukin-2. *J. Virol.* 79, 11205-11213
30. Mondal, B. A.K.Bear, M. Hosamani, P.A. Tembhurne, and S.K. Bandyopadhyay. 2006. Detection of ORF virus from outbreak in goat and its genetic relation with other parapoxviruses. *Vet Res Comm*, 30:531-539
31. Nobrega, J.J. J.T. Macedo, J.A. Araujo, A.F. Dantas, M.P. Soares, and F. Riet-Correa. 2008. Contagious Ecthyma in Sheep and Goats in the Semiarid of Paraiba, Brazil. *Pesquisa. Vet. Brasil.* 28(3): 135
32. Oem, J.K. I.S. Roh, K.H. Lee, K.K. Lee, H.R. Kim, Y.H. Jean, and O.S. Lee. 2009. Phylogenetic analysis and characterization of Korean ORF virus from dairy goats: case report. *Virol. J* 6(1), 167
33. Peralta, C. A. Robles, and A. Mart´inez. 2015. Identification and molecular characterization of ORF virus in Argentina, *Virus Genes*, 50, (3): 381-388
34. Said, A.A. Mohamed, S.I. Elhamid, W.A. Hosny, and E.M. Baheeg. 2013. Trials for isolation of contagious pustular dermatitis virus (CPDV) from sheep in Ismailia governorate. *Res. Zool.*, 3(1):10-14
35. Saitou, N. and M. Nei. 1987. The neighbour-joining method: A new method for reconstructing phylogenetic trees. *Molecular Biology and Evolution* 4:406-425
36. Salem, S.A.H. O.A. Shemies, N.A. Mahmoud, and A.A. Arafa. 2008. Isolation and Molecular Characterization of Camel Pox Virus. *Egypt. J. Comp. Path. & Clinic. Path* 21: 306-318
37. Seet, B.T. J.B. Johnston, C.R. Brunetti, J.W. Barrett, H. Everett, C. Cameron, J. Sypula, S.H. Nazarian, A. Lucas, and G. McFadden. 2003. Poxviruses and immune evasion. *Annu. Rev. Immunol.* 21, 377-423
38. Spyrou, V. and G. Valiakos. 2015. ORF virus infection in sheep or goats. *Vet. Microbial.*, 181: 178-182
39. Tryland, M. J. Klein, E.S. Nordøy, and A.S. Blix. 2005 Isolation and partial

characterization of a parapoxvirus isolated from a skin lesion of a Weddell seal. *Virus Res* 108: 83-87

40. Trylanda, M. J. Kleinb, T. Bergera, D.J. Terje, C.G. das Nevesa, A. Oksanend, and K. Asbakka. 2013. Experimental parapoxvirus infection (contagious ecthyma) in semidomesticated reindeer (*Rangifer tarandus tarandus*). *Vet. Microbiol.* 162(2–4): 499-506

41. Vikoren, T. A. Lillehaug, J. Akerstedt, T. Bretten, M. Haugum, and M. Tryland. 2008. A severe outbreak of contagious ecthyma (ORF)

in a free-ranging musk ox (*Ovibos moschatus*) population in Norway. *Vet Microbiol*, 127:10-20

42. Zeedan, G.S. M.A. Hassanain, and R.M. Shaapan. 2015. Isolation of Parapoxviruses from Skin Lesion of Man and Animals in Egypt *Global Veterinaria* 12 : 19-25

43. Zuckerkandl, E. and L. Pauling. 1965. Evolutionary divergence and convergence in proteins. Edited in *Evolving Genes and Proteins* by V. Bryson and H.J. Vogel, pp. 97-166. Academic Press, New York.