

## PREVENTATIVE EFFECTS OF PROBIOTIC (MIACLOST) ON EXPERIMENTALLY INDUCED HYPOCALCEMIC RICKETS IN BROILER CHICKS.

N. A. Ameen\*  
Lecturer

N. R. Abdul Rahman\*  
Assist. Prof.

A H Hassan\*\*  
Assist. Prof.

\*Dep. Anatomy and Pathology, Coll. Vet Med, University Sulaimani \*\*Coll.Dentistry University. Suliamania  
E-mail:nzarameen@yahoo.com

### ABSTRACT

A trial was conducted to study the effects of probiotic (Miaclost) supplement on experimentally induced hypocalcemic rickets in broiler chicks, a total of 180 one-day-old broiler chicks (Ross 308) were randomly divided into three equal groups 60 chicks per group with 3 replicates (20 birds /replicate) the dietary treatments consisted of a normal ration for G1, calcium-deficient ration 5% for G2 and calcium-deficient ration with addition of probiotics in drinking water for G3. Initial signs of rickets have been observed at 35-day of age in G2. while, in G1 and G3 no clinical signs observed, the gross lesions appeared enlargement of parathyroid gland, costochondral junction and increase in the width of growth plate of tibial bone of G2 whereas no gross lesions recorded in G1 and G3, the histopathological examination of parathyroid gland in G2 there were a focal parathyroid hyperplasia and increasing in numbers of syncytial cells and normal in G1 and G3, no intestinal histopathological changes in G1 and G2 and increase in height and width of the intestinal villi in probiotic group G3. Marked increase in the thickness of proliferation zone within growth plate of tibia bone in G2 and normal thickness in G1 and G3. the serum biochemical analysis of calcium of G2 recorded significantly low level in G2 and high level in G3 comparatively with G1, finally the serum alkaline phosphatase values were high significantly in G2 and normal in G3, it is concluded that probiotic (MiaClost) can be used as prophylaxis to prevent hypocalcemic rickets in broiler chicks

Key words: Calcium, parathyroid gland, tibial bone, proliferation zone

امين وآخرون

مجلة العلوم الزراعية العراقية - 2021: 52 (6): 1461-1474

التأثيرات الوقائية للمعزز الحيوي مياكلوست (MiaClost) على الكساح المحدث تجريبيا من نقص الكالسيوم في أفراس اللحم

\*علي حسين حسن  
أستاذ مساعد

\*نوزاد رشيد عبدالرحمن  
أستاذ مساعد

\*نزار علي امين  
مدرس

قسم التشريح والامراض - كلية الطب البيطري - جامعة السليمانية

### المستخلص

اجريت هذه التجربة لدراسة تأثيرات المعزز الحيوي (مياكلوست) على الوقاية من الكساح المحدث تجريبيا من نقص الكالسيوم في العليقة، مجموع مائة وثمانون من دجاج فروج اللحم روز 308 بعمر يوم واحد استخدمت في هذه التجربة ووزعت بشكل عشوائي على ثلاث مجاميع متساوية ستون فرخ لكل مجموعة وكل مجموعة مكونة من ثلاث مكررات، المجموعة الاولى غذيت عليقة طبيعية والمجموعة الثانية غذيت عليقة ناقصة الكالسيوم ( 5%) والمجموعة الثالثة غذيت عليقة ناقصة الكالسيوم مع اضافة المعزز الحيوي في ماء الشرب، في اليوم 35 وبعدها بدأت العلامات السريرية للكساح بالظهور في المجموعة الثانية اما المجموعة الاولى والثالثة فكانت طبيعية، وبينت الافات العيانية للمجموعة الثانية زيادة في حجم الغدة المجاورة للدرقية وزياد واضحة في حجم تمفصل العمود الفقري مع الاضلاع وكذلك زيادة في عرض صفيحة النمو الظنبوبي. الفحوصات النسجية للغدة المجاورة للدرقية للمجموعة الثانية بينت فرط التنسج البؤري وزيادة عدد الخلايا المخلووية اما المجموعة الاولى والثالثة كانت طبيعية، وزيادة في ارتفاع وعرض الزغابات في المجموعة الثالثة، لا تغيرات نسجية معوية في المجموعة الاولى والثانية وكذلك زيادة ملحوظة في سمك نطاق النكاثر ضمن صفيحة النمو للمجموعة الثانية وسمك طبيعي في بقية المجاميع. التحليلات الكيمياء الحيوية للكالسيوم في مصل أفراس المجموعة الثانية سجلت ادنى قيمة معنوية والمجموعة الثالثة اعلى قيمة معنوية بالمقارنة مع المجموعة الاولى وسجلت زيادة معنوية في قيمة انزيم الفوسفاتيز القلوية للمجموعة الثانية وطبيعية في المجموعة الثالثة. نستنتج من هذه النتائج بان المعزز الحيوي (مياكلوست) يمكن استخدامه للوقاية من الكساح الناتج من نقص الكالسيوم في العليقة.

الكلمات المفتاحية: الكالسيوم، الغدة المجاورة للدرقية، عظم الظنبوب، نطاق النكاثر

Received:22/10/2020, Accepted:24/1/2021

## INTRODUCTION

Producers of broiler chicks started use antibiotics as feed additives to increase the digestive system performance of broiler chickens, they are mainly used to prevent infections, treat infected animals and to stimulate growth (22). Unfortunately, the use of these medicines was wildly exaggerated and bacteria began to create resistance to them (22, 36). These situations demanded solutions to growth promoters and prevent infection. A search for fresh dietary alternative, namely probiotics (pro.) has been given increased attention. Pro. (MiaClost) was as efficient as antibiotics in controlling efficiency, including the ratio of body weight gain and feed conversion, and improving gut integrity by raising **Villus Height** and **Villus Height: Crypt Depth** ratio in broiler chicks threatened by E Coli, suggesting that MiaClost can act as a substitute for antibiotics to suppress E coli infection (29). Pro. are a preparations or substance containing a sufficient amount of efficient, specified live microorganisms (e.g. *Lactobacillus* and *Bifdobacteria*) that give the host a health benefit when administered in adequate quantities (49). In the gastrointestinal (GI) tract, these microorganisms compete with ingested pathogens, generate volatile fatty acids and stimulate immune responses to foreign microorganisms (7), Display inhibition action against bacterial infections (*Staphylococcus aureus*, *Pseudomonas aeruginosa*) (39), also (26) showed that the presence of active compounds in chamomile including (flavonoids, kamasolen and bisaboldaxid essential oils) that may act like pro. By enhancing the gastro intestinal normal microbial population and improving nutrient absorption. Additionally the pro. enhance the quality characteristics of Eggs in hens (23). Furthermore pro. and prebiotic can be used to lengthening the life span of fermented dairy products (25).

**Rickets** is a metabolic condition, defined by thickening of bone growth plates and inadequate mineralization in young growing chicks. Etiology is generally associated with the deficiency of nutritional calcium (Ca), phosphorus (P) and vitamin D3, impaired Ca/P ratio (2:1) or impaired absorption of one or both of these macroelements (11, 12). False

feed mixing may also cause outbreaks, the adequate calcification of the cartilage is impaired in both types (Ca-deficiency and P-deficiency) (11). To our knowledge, there is no data available on the impact of pro. on calcium deficiency rickets in broiler chicks. Therefore, the aim of this study is to explore the possibility of using pro. for prevention of calcium deficiency rickets in broiler chicks.

## MATERIAIS AND METHODS

A field experiment was conducted at the agricultural experiment unit, College of Agriculture Engineering Sciences, University of Sulaimani, to study the effects of Miaclost pro. (*Bacillus subtilis* and *Enterococcus faecium*) supplements on experimentally induced hypocalcemic rickets in broiler chicks, A total of 180, one-day-old, broiler chicks (Rose 308), obtained from Kosar Company for Agriculture and Poultry were randomly assigned into 3 groups (3 replicates each, 20 chicks / replicate) and housed in separate, temperature, ventilation & light-controlled pens. The experimental rations were formulated by manufactured company to contain 0.5% calcium and fixed levels of Phosphorus, the diets were prepared to fulfill the standard requirements of broiler chicks (with no antibiotics or growth promoter supplementations). From one day old the chicks in G2 received ration deficient in calcium without MiaClost pro. while G3 received ration deficient in calcium with MiaClost pro. as directed by manufactured companies in drinking water, whereas the control group's chicks (G1) were left without treatment free drinking water and normal ration. At the end of weeks 1, 2, 3, 4, 5, and 6, two chicks were randomly selected from each replicate (8 birds / group), euthanized by slaughtering and the procedure of blood samples collection was carried out followed by putting blood samples obliquely in sterile clean plastic test tubes without anticoagulants. This procedure is achieved for estimation of serum calcium, serum phosphorus and serum alkaline phosphatase weekly. After that the slaughtered chickens dissected for two reasons; first to observe the gross lesions in the affected organs and second to obtain tissue samples (parathyroid gland, intestine and tibia bone) for histopathological examination. the

histological preparations and staining achieved according to (46), and 2 cm long tibial bones specimens were decalcified according to (5). The SAS statistical package (PROC GLM) was used to determine significance of main effects (SAS, 2013). Duncan's multiple range tests was used to detect the differences between individual treatment means. Statistical significant was declared at ( $p < 0.05$ ).

## RESULTS AND DISCUSSION

Generally, at the end of each week (1, 2, 3 and 4) of the chickens age there were no changes or statistical significant differences recorded of all studied parameters between the groups of the experiment, while, following this period the pathological changes were start to observed and there were a significant differences at ( $P < 0.05$ ) between the mean values of parameters of the study

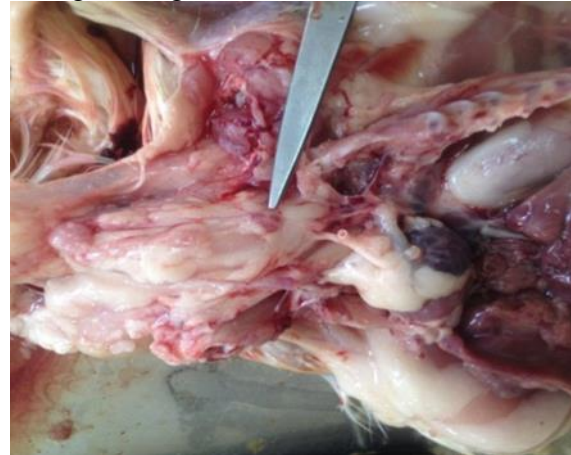**Clinical signs:** basically, in calcium deficient groups the initial signs of rickets have been observed at and after 35 day of age, manifested with usual signs – various extent of leg weakness – from unstable gait to complete inability of chickens to stand up, lying down on their bent legs or on their side. Some of affected chickens used their wings for support when moving Fig 1.



**Figure1. Typical characteristic clinical sings of rickets, unstable gait to complete inability of chicken to stand up, lying down on their bent legs**

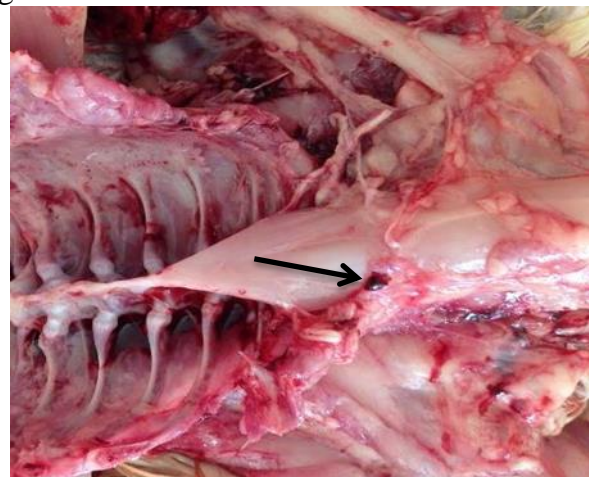
**Gross findings of the parathyroid glands:** The main organ affected by calcium deficient ration is parathyroid gland, normally this organ is very small and it is difficult to recognized easily by naked eye, while, when there is calcium deficiency in the ration it is recognized easily due to sever enlargement of

the organ this condition is clearly appeared in affected chickens of G2 Fig 2. On day 42, the gross examination of the parathyroid glands in the control negative chickens (G1 fed on normal rations) showed normal gland size, and in the control positive chickens G2 (which fed calcium-deficient rations) marked enlargement of the gland fig(2).



**Figure 2. Parathyroid glands of 42 days old chicken of G2 marked parathyroid gland enlargement**

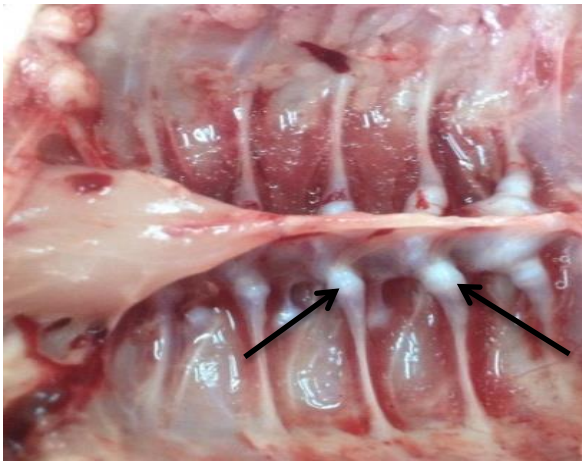
In the pro. group G3 (which fed calcium-deficient rations and supplemented with pro. in drinking water) showed normal size of the glands Fig 3 there is no enlargement in the gland.



**Figure 3. Parathyroid glands of 42 days old chicken of G3 normal size of the gland no parathyroid enlargement**

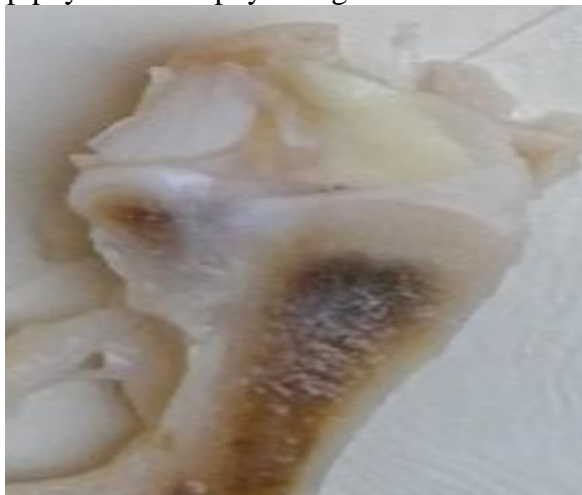**Gross findings of the ribs and tibia bone:** On day 42, the gross examination of the control positive chickens G2 revealed rachitic rosary manifestation of the costochondral junctions (rickets specific gross lesions) due to bulbous swelling of the ventral ribs' ends Fig 4, and softness of the tibial bones





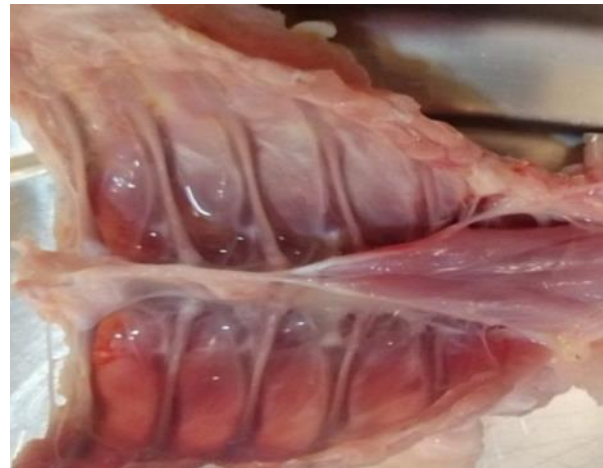**Figure 4. Costochondral junctions of 42 days old chicken of G2, rachitic rosary manifestation and enlargement of Costochondral junctions**

In addition, the epiphyseal growth plate in the tibial bones exhibited a fuzzy (ill-defined) appearance, increase in its width, and lack of distinct borders separating it from the epiphysis and diaphysis Fig 5.

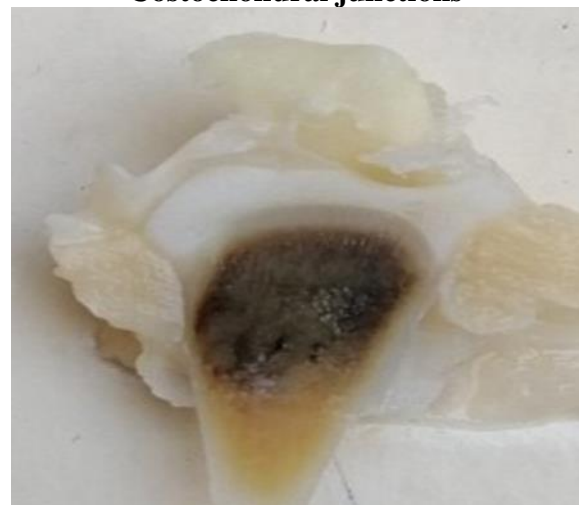

**Figure 5. Tibial growth plate of 42 days old chicken (G2) showed a fuzzy appearance, marked increase in width, and lack of distinct borders separating it from the epiphysis and diaphysis**

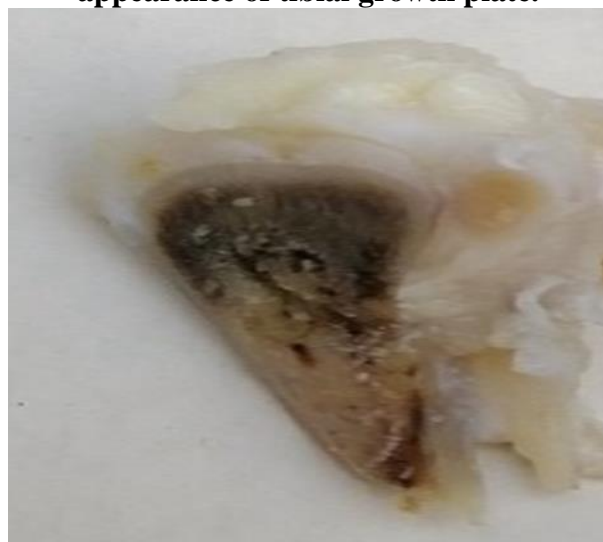
While in the chickens of the G3 showed normal manifestation of the costochondral Junctions Fig 6, no softening and approximately normal morphology of the growth plates Fig 7.



**Figure 6. Costochondral junctions of 42 days old chicken of G3 No enlargement of Costochondral junctions**



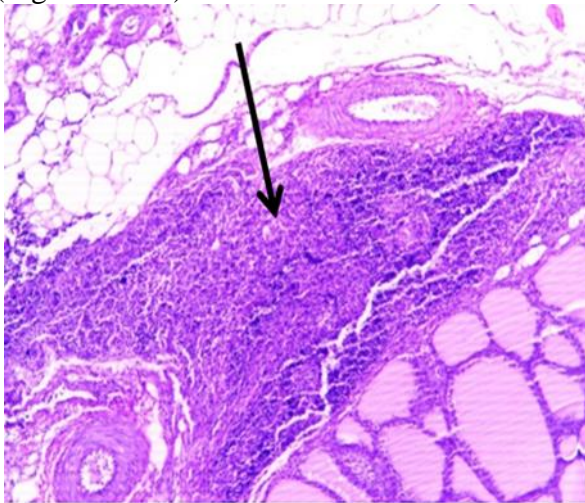
**Figure 7. Pro. group (G3) normal appearance of tibial growth plate.**



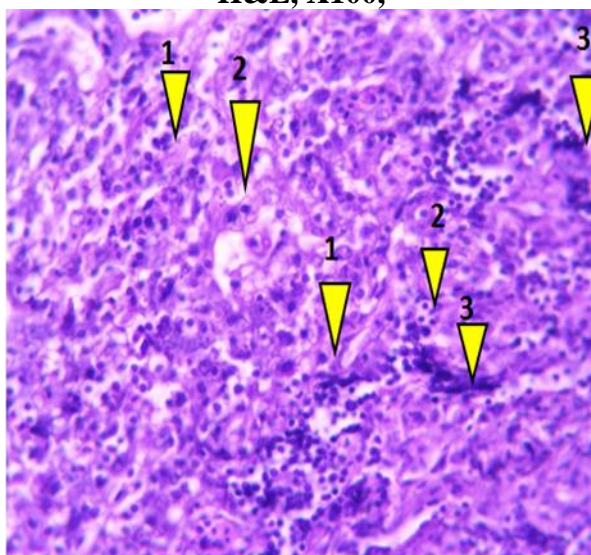
**Figure 8. Normal appearance of tibial growth plate of 42 day's old chickens (G1). Histopathological findings of the parathyroid gland of the chickens in control negative group which were fed balanced rations showed normal morphological characteristics of the**



gland, no oxyphil cells were found and Multinucleated syncytial cells were also seen (Fig. 9 and 10).

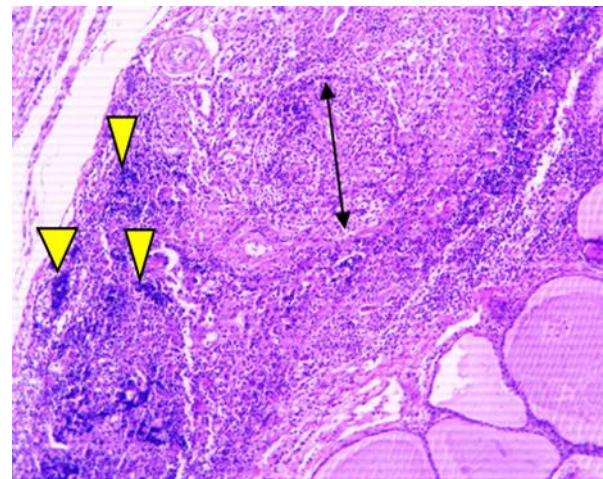


**Figure 9. Microscopic view of a parathyroid gland section of G1 shows normal morphological characteristics of the gland H&E, X100,**

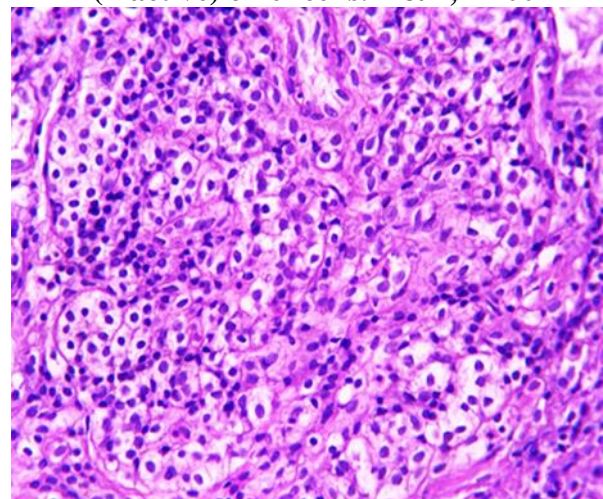


**Figure 10 . Microscopic view of a parathyroid gland section of G1 Shows normal morphological characteristics of the gland 1. Active (dark) chief cells, 2. Inactive (light) chief cells and 3. Multinucleated syncytial cells. H&E, X400**

On the other hand, the microscopic examination of the parathyroid glands in chickens of the control positive group (G2) shows focal parathyroid hyperplasia and increasing in numbers of syncytial cells (Fig 11 and 12). The hyperplastic focus consisted mainly from hypertrophied light staining (inactive) chief cells.



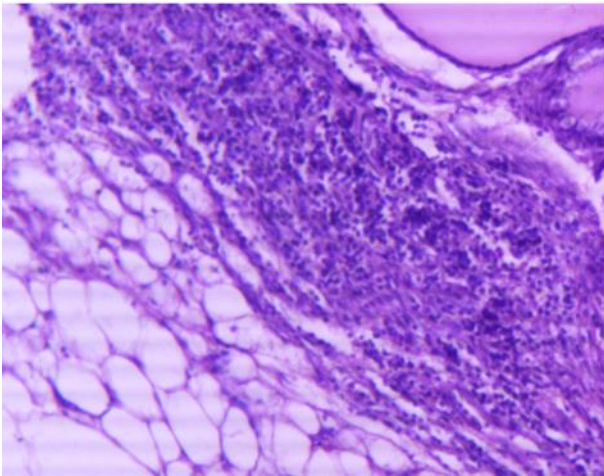
**Figure 11. Microscopic view of a parathyroid gland section of G 2 Shows focal hyperplasia (black double-headed arrow) and increasing in numbers of syncytial cells (yellow arrow heads) are also apparent and hypertrophied light staining (inactive) chief cells. H&E, X100**



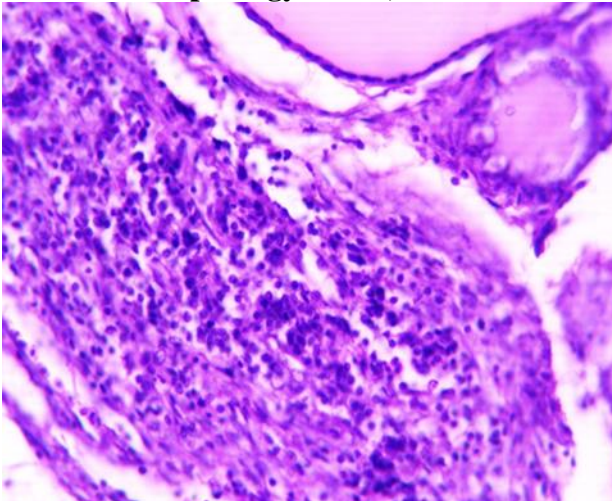
**Figure 12. Microscopic view of a parathyroid gland section of G 2 Shows apparent and hypertrophied light staining (inactive) chief cells. H&E, X400**

Regarding to G3 shows approximately normal morphological characteristics of parathyroid gland (Fig. 13 and 14).

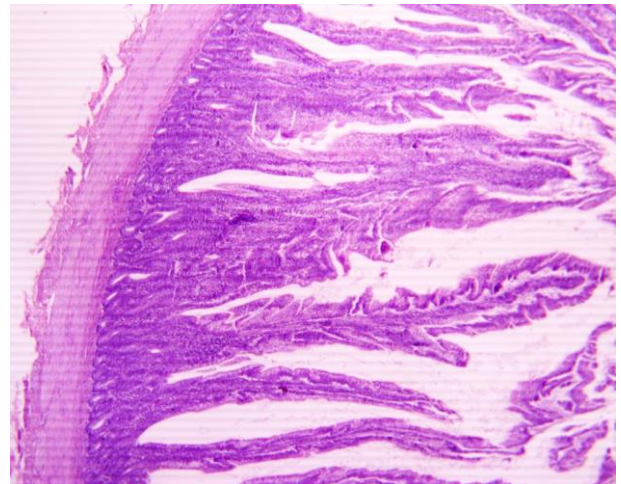




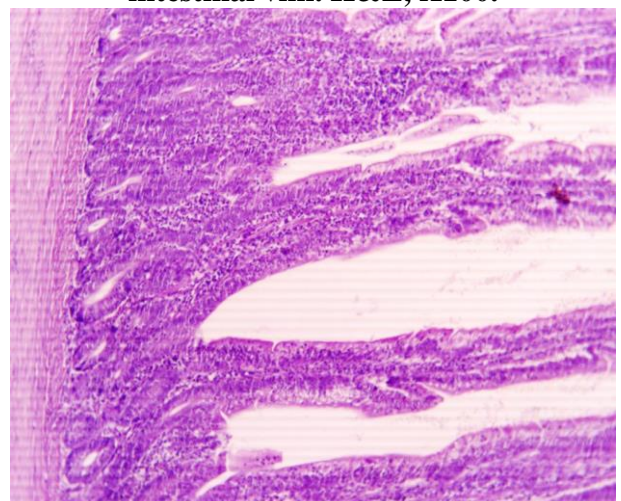
**Figure 13. Microscopic view of a parathyroid gland section of G3 shows approximately normal parathyroid gland morphology. H&E, X200**



**Figure 14. Microscopic view of a parathyroid gland section of G3: shows approximately normal parathyroid gland morphology. H&E, X400**



**Figure 15.A. Microscopic view of a small intestinal section of G3. It shows marked increase in the height and width of the intestinal villi. H&E, X100.**

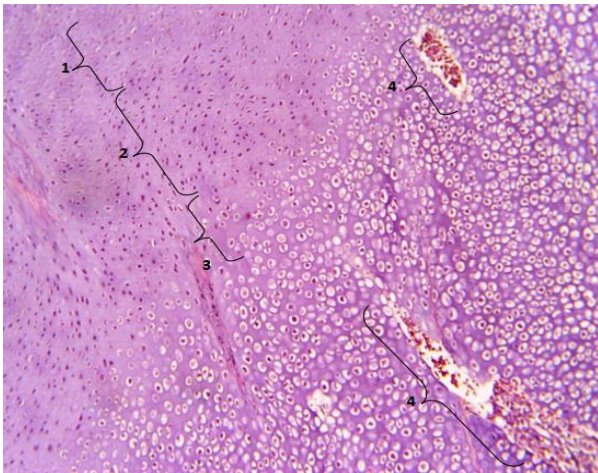


**Figure 15.B . Higher magnification view of the small intestinal section shown in figure . It shows marked increase in the height and width of the intestinal villi. H&E, X400.**

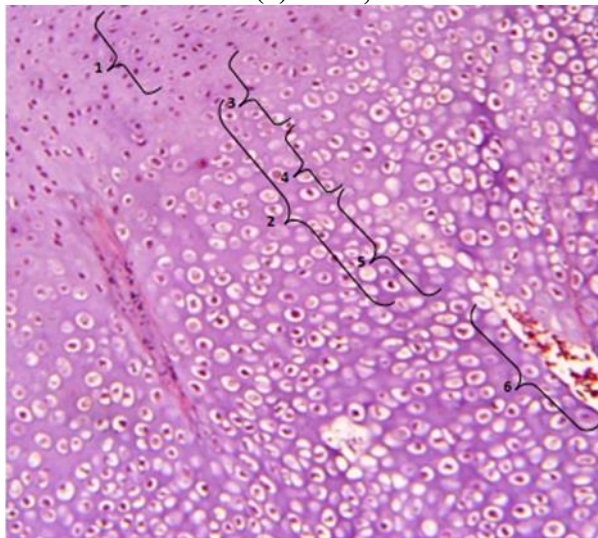
**Histopathological findings of the small intestine:** The microscopic examination of the small intestine in chickens of the groups (1 and 2) shows normal appearance of the height and width of the intestinal villi. While the microscopic examination of the small intestine in chickens of G3, shows marked increase in height and width of the intestinal villi (Fig.15A and 15 B) and consequently marked increase in the absorption surface area

**Histopathological findings of the tibial of the chickens in control negative group** which were fed balanced rations showed normal thickness of the reserve, proliferation & hypertrophic zones within the growth plate (Fig 16 and 17).





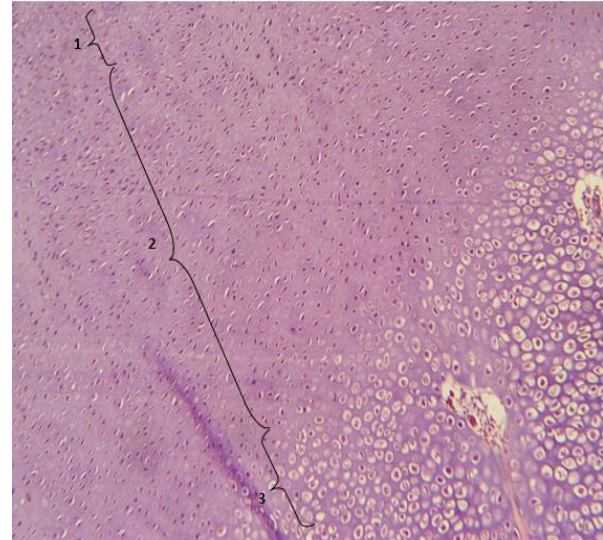
**Figure 16. Microscopic view of a tibial bone section of G1 shows normal thickness of the reserve (1), proliferation (2) and hypertrophic (3) zones within the growth plate and two blood vessels (4) H&E, X100**



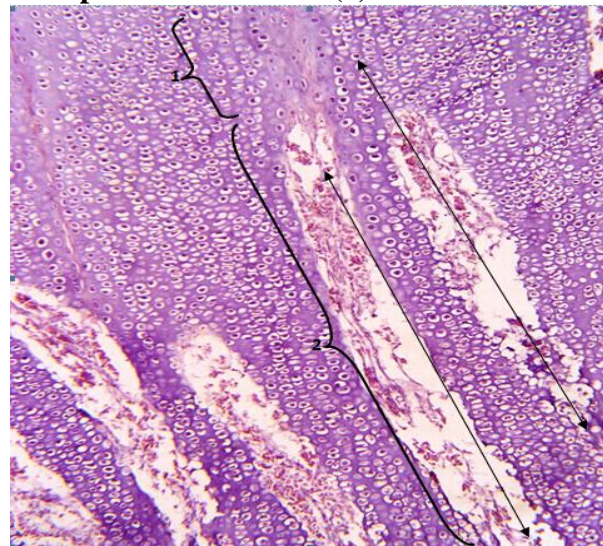
**Figure 17. Higher magnification view of pervious figure shows the distal part of the proliferation zone consisting of proliferating chondroblasts (1) and the hypertrophic zone (2) which consists of three sub-zones including the maturation zone consisting of mature chondrocytes within their lacunae (3), degeneration zone consisting of degenerating chondrocytes (4) and provisional calcification zone consisting of dead chondrocytes with pyknotic or karyolytic nuclei (5). An invading blood vessel (6) is apparent in the proximal part of the diaphyseal primary spongiosa. H&E, X200**

Whereas, the tibial bones of chickens in G2 showed a marked increase in the thickness of the proliferation zone (fig 18) resulting in formation of cartilaginous projections extending out from the growth plate and intersecting with the diaphyseal primary spongiosa (Fig 19). The chondrocytes in these

cartilaginous projections do not show any sign of degeneration or necrosis.



**Figure 18. Microscopic view of a tibial bone section of G2 shows normal thickened reserve zone (1) & hypertrophic zones (3) and marked increase in the thickness of the proliferation zone (2). H&E 100X**

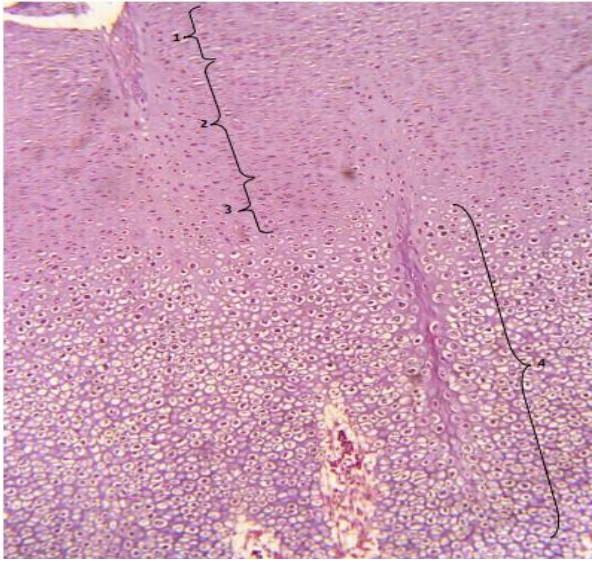


**Figure 19. Microscopic view of a tibial bone section of G2 Shows cartilaginous projections (black, double headed arrows) are seen extending out from the growth plate and intersecting with the primary spongiosa. The chondrocytes in these cartilaginous projections do not show any degenerative or necrotic changes. H&E 100X**

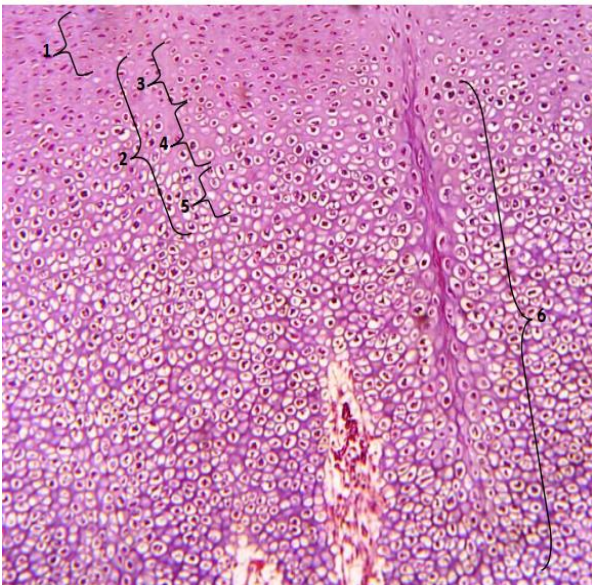
While, the microscopic examination of the tibial bones of chickens in G3 showed approximately normal growth zones approximately similar to that seen in the G1. No increase in thickness was seen in the reserve and hypertrophic zones and only a very little increase in thickness was seen in the



proliferative zone within the growth plate (fig 20 and 21).



**Figure 20. Microscopic view of the growth plate of G3 shows normal thickened reserve zone(1) and hypertrophic(3) zone and only little increase in the thickness of the proliferation(2) zone. Three invading blood vessel are apparent in the proximal part of the diaphyseal primary spongiosa (4). H&E, X100.**



**Fig. 21. Higher magnification view of previous figure shows the distal part of a proliferation zone consisting of proliferating chondroblasts (1) and slightly thickened hypertrophic zone (2) consisting of three sub-zones including the maturation zone consisting of mature chondrocytes within their lacunae (3), degeneration zone consisting of degenerating chondrocytes (4) and provisional calcification zone consisting of dead chondrocytes with pyknotic or karyolytic nuclei (5). Three invading blood vessel are apparent in the proximal part of the diaphyseal primary spongiosa (6). H&E, X200**

Regarding to the **biochemical examinations** of the experiment the results were as follows, from the beginning of the experiment till the 5<sup>th</sup> week of the chickens age there were no significant differences at ( $P<0.05$ ) between the mean value of serum calcium of all the groups of the experiment, while, following this period there were a significant differences at ( $P<0.05$ ) between the mean values of serum calcium at and after 35-37 day of chickens age recorded in the groups of experiment were as follow (G1  $9.487\pm 0.103$ ), (G2  $9.287\pm 0.103$ ), (G3  $9.564\pm 0.103$ ), as shown in Table 1. G1 recorded the highest mean value among the groups while G2 recorded the lowest mean value between the groups of the experiment. Additionally there were no significant differences at ( $P<0.05$ ) between the mean value of serum calcium of the groups G1 and G3, at and after 35-37day of chickens age. Concerning to the mean value of serum alkaline phosphatase of the groups of experiment mainly, from the starting of the experiment until the week 5<sup>th</sup> of the chickens age there were no significant differences between the mean value of serum alkaline phosphatase (ALP) of all the groups of the experiment, whilst, following this duration there were a significant differences at ( $P<0.05$ ) between the mean values as follow (G1  $676.346\pm 11.008$ ), (G2  $715.556\pm 11.008$ ), (G3  $705.889\pm 11.008$ ), as shown in Table 2 . G1 recorded the lowest mean value in comparison with other groups and G2 recorded the highest mean value comparatively with remaining groups of the experiment also there were no significant differences between the mean value of serum ALP of the groups G1and G3 at and after 37 day of chickens' age.



**Table 1. Serum calcium mean values of experiment from (1-6) week in different groups, Values are mean  $\pm$  SE**

Weeks Groups	W1	W2	W3	W4	W5	W6
G1	9.487 $\pm$ 0.103 a	9.377 $\pm$ 0.085 a	9.817 $\pm$ 0.082 a	9.667 $\pm$ 0.085 a	9.611 $\pm$ 0.074 a	9.568 $\pm$ 0.072 a
G2	9.287 $\pm$ 0.103 a	9.121 $\pm$ 0.085 a	9.278 $\pm$ 0.082 a	9.111 $\pm$ 0.085 a	8.944 $\pm$ 0.074 b	8.210 $\pm$ 0.072 b
G3	9.564 $\pm$ 0.103 a	9.621 $\pm$ 0.085 a	9.688 $\pm$ 0.082 a	9.611 $\pm$ 0.085 a	9.567 $\pm$ 0.074 a	9.449 $\pm$ 0.072 a

a, b means in rows with different superscripts are significantly different ( $P < 0.05$ ), Values followed by different letters on the table are significantly different ( $P < 0.05$ ). The symbol (G) represents the group and (W) represent Week

**Table 2. Serum Alkaline Phosphatase mean values of experiment from (1-6)week in different groups, Values are mean  $\pm$  SE**

Weeks Groups	Week1	Week2	Week3	Week4	Week5	Week6
G1	715.889 $\pm$ 3.809 a	693.7778 $\pm$ 10.946 a	693.222 $\pm$ 11.16 a	682.4567 $\pm$ 11.41 a	676.346 $\pm$ 11.008 a	671.568 $\pm$ 9.13 a
G2	716.222 $\pm$ 3.809 a	694.3333 $\pm$ 10.946 a	718.778 $\pm$ 11.16 a	696.5556 $\pm$ 11.41 a	715.556 $\pm$ 11.008 b	729.111 $\pm$ 9.13 b
G3	705.778 $\pm$ 3.809 a	705.8889 $\pm$ 10.946 a	702.444 $\pm$ 11.16 a	702.6667 $\pm$ 11.41 a	705.889 $\pm$ 11.008 ab	691.111 $\pm$ 9.13 a

a, b means in rows with different superscripts are significantly different ( $P < 0.05$ ), Values followed by different letters on the table are significantly different ( $P < 0.05$ ). The symbol (G) represents the group and (W) represent Week

Probiotics may have a possible influence on bone accumulation, which may occur through microbial activity of metabolites or enzymes or synthesis of vitamins (18, 8). The point is that the significant histological improvements in calcium deficient ration groups supported by pro. happened in the chickens intestine indicates that they may have suppressed and occupied the growth of rachitic bone lesions due to calcium deficiency in the experiment; Thus, there were no visible clinical signs in the experiment group 3 till the termination of the experiment. The clinical signs of G1 (fed balanced rations), revealed normal clinical signs, in contrast, the clinical signs in chickens of G2 (fed calcium-deficient rations) showed typical signs of hypocalcemic rickets. This finding can be attributed to the effects of calcium deficiency which is in agreement with those of (11, 12). In G3 (and fed on calcium-deficient rations supplemented with pro. in drinking water), showed approximately normal clinical sings. This finding indicates a reliable prophylaxis effect of pro. against the effects of calcium-deficiency in the diet through several normocalcemic-inducing mechanisms such as increasing the solubility of minerals & increasing the absorption surface area of the intestinal epithelium (40), enhancement of vitamin D receptor expression on the intestinal epithelial cells (38) and increasing the rate of calcium absorption by the small intestinal tract (40, 48, 30).

**Gross Findings of the Parathyroid Glands:** the enlargement of the parathyroid gland in G2, can be attributed to the hypertrophy and hyperplasia of the chief cells of the glands as an attempt to neutralize the effects of calcium deficiency (37, 4). On the other hand, normal-sized parathyroid glands in G3, indicates that such supplementation could relieve the increase for functional demand of the parathyroid glands because of the dietary calcium deficiency by increasing the rate of calcium absorption through the small intestinal tract (17,48, 30), increasing the solubility of minerals & increasing the absorption surface area of the intestinal epithelium (40). Related to **Gross findings of the ribs and tibial bones** G2 These findings which are generally in agreement with related works (3,13) can be attributed to the abnormal configuration of the metaphysis due to accumulation of non-mineralized osteoid in the zone of provisional calcification of the growth plates (10, 44). In addition, softness of the tibial bones. This finding which is in agreement with those of (3) and (42) can be ascribed to the decrease in bone mineral density (24) because of the dietary-induced hypocalcemia. While, in G3 showed normal manifestation of the costochondral joints, and normal morphology of the tibial growth plates. These findings which are in agreement with (15) and (1) who observed that the pro. enhanced the calcium absorption level, bone mineralization, bone

mineral content and bone density and they indicate that the supplementation by pro. could provide a reasonable prophylaxis against the injurious effects of diet calcium-deficiency on the bone development process in the chickens perhaps through increasing calcium absorption through the small intestinal tract (48, 30) and through enhancing microbial synthesis of metabolites, enzymes or vitamins such as D, C, K and folate which are involved in calcium metabolism and synthesis of the bone matrix and accretion of the bone (8, 40). Related to **histopathological examination** of the parathyroid glands in the G1 revealed normal morphological characteristics of the gland. Oxyphil cells, which are present in the parathyroid glands of mammals such as human, equines and cattle (21) were not seen in the present study. This result is compatible with the results of other avian parathyroid studies which reported the lack of oxyphil cells (9). Interestingly, multinucleated syncytial cells have been observed and reported for the first time during the present study in the avian parathyroid glands. These cells, which are believed to be formed by cytoplasmic fusion of adjacent chief cells, have been observed in human, canine and murine parathyroid glands (41). In contrast, the microscopic examination of the parathyroid glands in G2 showed focal parathyroid hyperplasia. This finding which is in agreement with those of (14, 47) can be attributed to the gland response to the stress of calcium deficiency because the parathyroid glands play an important role in regulation and maintenance of a normal calcium levels in the blood (4). The hyperplastic focus consisted mainly of hypertrophied light staining (inactive) chief cells. This result is constant with those of (41) and it can be ascribed to the fact that the light staining chief cells have become inactive after passing through a period of activity during which they release their secretory products (32). In addition, increasing in numbers of syncytial cells. This interesting finding possibly indicates a proportional correlation with the parathyroid gland activity. In the G3 chickens, the microscopic examination of the parathyroid glands showed approximately normal parathyroid morphological characteristics. This finding

indicates a reliable prophylaxis effect of this supplement against the effects of calcium-deficiency in the diet on the parathyroid histomorphology through several normocalcemic-inducing mechanisms such as increasing the solubility of minerals & increasing the absorption surface area of the intestinal epithelium (40), enhancement of vitamin D receptor expression on the intestinal epithelial cells (38) and increasing the rate of calcium absorption by the small intestinal tract (48,30). **The Histopathological Findings of the Small Intestine:** Compared to G1 and G2 which showed normal gross appearance, normal microscopic morphology and normal height, depth and width of the intestinal villi; the microscopic examination of the small intestine in chickens of the G3 showed marked increase in height and width of the intestinal villi and consequently marked increase in the absorption surface area. This improvement is possibly attributed to the ability of the pro. bacteria to enhance the intestinal mucosa through amelioration of the epithelial injury (43), inhibition of epithelial cells' apoptosis (50), regulation of the expression & distribution of the epithelial tight junction proteins (31, 35), prevention of pathogens adherence (45) and regulation of mucus secretion (6). The improvement in the intestinal morphology seen in this study is in agreement with similar findings reported by (19) and (16). However, it disagrees with the findings of (2) who stated no significant differences in height, depth, or width of the intestinal villi; this disagreement can be attributed to differences in the dose, way of administration & species of microorganism found in the concerned pro. and to animal characteristics (species, age, stage of production and health status) & housing conditions (30). **Histopathological Findings of the tibial Bones of G2** This increase in thickness of the proliferation zone within the growth plate and the excessive osteoid deposition are possibly attributed to the delay in the calcification process due to hypocalcemia (27) and they are generally in agreement with the findings of (33) who revealed that the trabecular bone of hypocalcemic growing rats' tibial bones showed that the central parts of the trabeculae



were calcified, whereas the peripheral bone matrix were composed of thick, uncalcified osteoid borders and they are also in agreement with the results of (28) who observed deficient mineralization and irregular, disordered columns of a continued cartilaginous proliferation in the growth plate resulting in penetration of the other zones in the growth plate in the fore limbs' bones of a 6-month-old monkey with rickets. In chickens of G3 showed approximately normal growth plate zones. This finding, which is in agreement with (34) who observed that the pro. increased the calcium absorption level, bone mineral content and bone density in the growing rats. This prophylactic effect of the pro. is referring to a conceivable prophylaxis effect of these supplements against the deleterious effects of calcium-deficiency in the diet on the process of bone development in the chickens via increasing the solubility of minerals (40) and facilitating mineral absorption through the small intestinal tract (30) and via microbial synthesis of metabolites, enzymes or vitamins (8) because certain vitamins such as D, C, K and folate are involved in calcium metabolism and are also required for synthesis of the bone matrix and accretion of the bone (40).

**Biochemical analysis:** This finding indicates that such supplementation (probiotic) could relieve the increase for functional demand of the parathyroid glands because of the dietary calcium deficiency by increasing the rate of calcium absorption through the small intestinal tract (30), increasing the solubility of minerals & increasing the absorption surface area of the intestinal epithelium (40). Regarding to the serum alkaline phosphatase, this finding of G2 result of hyperactivity under physiological conditions (hypocalcemia) and is an attempt to compensate the stress result from calcium deficiency in the ration (37,4). While, the normal levels of serum ALP of the G3, indicates that such supplementation could relieve the increase for functional demand of Serum ALP because of the dietary calcium deficiency by increasing the rate of calcium absorption through the small intestinal tract (30), increasing the solubility of minerals & increasing the absorption surface area of the intestinal epithelium (40). Totally and finally, pro. can be used as prophylaxis to prevent

hypocalcemic rickets in broiler chickens, also the Broiler chickens in this study appeared to be highly efficient at utilizing Ca at low levels of dietary Ca (0.5%). This improved efficiency might have been due to increased intestinal absorption of Ca as a result of up-regulation of plasma and intestinal 1,25-dihydroxycholecalciferol concentrations, with a consequent increase in the concentration of duodenal calbindin, a protein which lines the gut and binds Ca from the lumen., this result is in accordance to the result of (47) whom showed increase in calcium retention, when levels of reduction of Ca are higher than 30%.

#### REFERENCES

1. Abrams, S.A., I.J. Griffin, K.M. Hawthorne L. Liang, S.K. Gunn G. Darlington, and K.J. Ellis, 2005. A combination of prebiotic short- and long-chain inulin type fructans enhances calcium absorption and bone mineralization in young adolescents. *Am J Clin Nutr*, 82:471–6.
2. AL-Jumaa, Y., H. LeyvaJimenez, A. Alsadwi, K. Gardner, R. Abdaljaleel and C. Bailey, 2018. Evaluation of *Saccharomyces cerevisiae* products and *Bacillus* on Broiler Performance. *Poultry Science Association 107<sup>th</sup> Annual Meeting*, 97(E-Supplement 1).
3. Anderson, H. C., J. B. Sipe, L. Hesse, R. Dharmyramaju, E. Atti, N. P. Camacho and J. L. Millán, 2004. Impaired calcification around matrix vesicles of growth plate and bone in alkaline phosphatase-deficient mice. *The American Journal of pathology*, 164(3), 841-847.
4. Bose S, and V.K., Das, 2012. A morphological study of calcium regulating glands in Yellow footed green pigeon, *Treron phoenicoptera phoenicoptera* (Latham). *GERF Bulletin of Biosciences*. 3(1):1-6.
5. Brown R.S.D., J. Edwards, J.W. Bartlett, C. Jones, and A. Dogan, 2002. Routine acid decalcification of bone marrow samples can preserve DNA for FISH and CGH studies in metastatic prostate cancer. *J. Histochem. Cytochem.* 50: 113-116
6. Caballero-Franco, C., K. Keller, C. De Simone and K. Chadee, 2007. The probiotic formula induces mucin gene expression and secretion in colonic epithelial cells. *Am J Physiol Gastrointest Liver Physiol*, 292, (1) : 315-232

7. Chambers, J.R. 2003. Probiotics for control of Salmonella in chicken. Canadian Meat Science Association News, September 2003, 6–9
8. Crittenden R.G., N. R. Martinez, and M.J. Playne 2003. Synthesis and utilisation of folate by yoghurt starter cultures and probiotic bacteria. *Int J Food Microbiol*,80:217–22
9. Dar, F.A., S. Maya, J.J. Chungath, N. Ashok, H.S. Patki, and K.S. Prashanth 2013. Histomorphological study of the parathyroid gland in female Kuttanad ducks (*Anas platyrhynchos domesticus*). *Veterinary World* 6(11): 941-944
10. Dibner, J. J., J. D. Richards, M. L. Kitchell, and M. A. Quiroz. 2007. Metabolic challenges and early bone development. *J. Appl. Poult. Res.* 16:126–137
11. Dinev I., 2011. Comparative pathomorphological study of rickets types in broiler chickens. *Iranian Journal of Veterinary Science and Technology* 3, ( 1 ): 2011, 1-10
12. Dinev, I., D. Kanakov, I. Kalkanov, S. Denev, and S. Nikolov, 2019. Comparative pathomorphologic studies on the incidence of fractures associated with leg skeletal pathology in commercial broiler chickens. *avian diseases* 63(4):641
13. Fleming, R. H., H. A. McCormack, L. McTeir, and C. C. Whitehead, 2006. Relationships between genetic, environmental and nutritional factors influencing osteoporosis in laying hens. *British Poultry Science*, 47(6), 742-755
14. Gautier, A.E., C.L. Walk, and R.N. Dilger, 2017. Influence of dietary calcium concentrations and the calcium-to-nonphytate phosphorus ratio on growth performance, bone characteristics, and digestibility in broilers. *Poultry Science* 96:2795-2803
15. Ghanem, K., I. Badawy, and A. Abdel-Salam, 2004. Influence of yoghurt and probiotic yoghurt on the absorption of calcium, magnesium, iron and bone mineralization in rats. *Milchwissenschaft*, 59(9-10),pp: 472-475
16. Ghenioa A.M., K.M. Ashry, A.M. Nazem, 2015. Protective effect of probiotic bactosac® against induced sub chronic lead toxicity in broiler chicks. *alexandria Journal for Veterinary Sciences*. 1:47(1).
17. Gilman, J. and K. D. Cashman, 2006. The effect of probiotic bacteria on transepithelial calcium transport and calcium uptake in human intestinal-like Caco-2 cells. *Curr Issues IntestMicrobiol*, 7(1): 1-5
18. Hancock R.D. and R. Viola, 2001. The use of micro-organisms for L-ascorbic acid production: current status and future perspectives. *ApplMicrobiolBiotechnol*, 56:567–76
19. Hassanpour H, A.K. Zamani, M. Khosravi and M. Mayahi, 2013. Effects of synbiotic on the intestinal morphology and humoral immune response in broiler chickens. *Livestock Science*. 153: 116-122
20. Hill C., F. Guarner and G. Reid, 2014. Expert consensus document: The International Scientific Association for probiotics and prebiotics consensus statement on the scope and appropriate use of the term probiotic. *Nat Rev Gastroenterol Hepathol* 11:506–514
21. Hullinger, R. and O.M. Andrisani, 2006. *Endocrine System*. In: Eurell JA and Frappier BL (Eds). *Dellmann’s Textbook of Veterinary Histology*, 6th ed. Black Well Publishing Ltd. pp: 298-319
22. Hume, H.E. 2011. Historic perspective: prebiotics, probiotics and other alternatives to antibiotics. *Poultry Science*, 90: 2663–2669
23. Jasim S. M. and A. Y. Taha 2017. Effect of supplementation of probiotic and citric acid to laying hens diet on eggs quality traits. *The Iraqi Journal of Agricultural Sciences* 48(2). 589-597
24. Jendral, M. J., D. R. Korver, J. S. Church, and J. J. R. Feddes, 2008. Bone mineral density and breaking strength of white leghorns housed in conventional, modified, and commercially available colony battery cages. *Poultry Science*, 87(5), 828-837
25. Khaleel, M .M. and K. Thaeer, 2017. Using probiotics and inulin to prolong fermented dairy products shelf life. *Iraqi Journal of Agricultural Sciences*. 48, 2.608-617
26. Khishtan, A. T. M. and S. S. M. Beski 2020. Delivery route of chamomile on the growth and subsequent physiology of broiler chickens under e. coli challenge. *Iraqi Journal of Agricultural Sciences*: 51(4): 1058-1073
27. Levine, B.S., M. Rodríguez and A.J. Felsenfeld, 2014. Serum calcium and bone: effect of PTH, phosphate, vitamin D and



- uremia. *Nefrología* (English Edition), 1:34(5):658-69
28. Liu, S.K. 2002. Metabolic disease in animals. *seminars in musculoskeletal radiology*, 6(04): 341-346
29. M'SADEQ S. A. 2019. Effect of dietary supplementation of miaclost on performance and gut morphology in broiler chickens challenged with *escherichia coli*. *Iraqi Journal of Agricultural Sciences*: 50(2):506-514
30. Matur, E. and E. Eraslan, 2012. The Impact of Probiotics on the Gastrointestinal Physiology. In: Tomasz Brzozowski (Ed.), *New Advances in the Basic and Clinical Gastro Enterology*. pp:51-74
31. Mennigen, R. and M. Bruewe, 2009. Effect of probiotics on intestinal barrier function molecular structure and function of the tight Junction. *Ann NY AcadSci*, 1165: (183–189
32. Mense, M.G. and T.J. Rosol, 2018. Parathyroid Gland. In: Suttie AW (ed.). *Boorman's Pathology of the Rat: Reference and Atlas*. 2<sup>nd</sup> ed. Academic Press.pp: 687-693.
33. Mocetti, P., P. Ballanti, S. Zalzal, G. Silvestrini, E. Bonucci and A. Nanci, 2000. A histomorphometric, structural, and immunocytochemical study of the effects of diet-induced hypocalcemia on bone in growing rats. *Journal of Histochemistry and Cytochemistry*, 48(8):1059-77
34. Narva, M., M. Collin, C. Lamberg-Allardt, M. Karkkainen, T. Poussa, H. Vapaatalo and R. Korpela, 2004. Effects of long-term intervention with *Lactobacillus helveticus*-fermented milk on bone mineral density and bone mineral content in growing rats. *Ann NutrMetab*, 48: 228–34
35. Ng, S.C., A.L. Hart, M.A. Kamm, A.J. Stagg and S.C. Knight, 2009. Mechanisms of action of probiotic: Recent Advances. *Imflamatuar Bowel disease*, 15 (2): 300-310
36. Nhung, N.T.C, N. hansiripornchai, and J.J. Carrique-Mas, 2017. Antimicrobial resistance in bacterial poultry pathogens: a review. *Frontiers in Veterinary Science*, 4: 126
37. Norris, D.O. 2007. *Vertebrate endocrinology*.4<sup>th</sup> ed. Academic Press.pp: 507-508
38. Resta, S.C. 2009. Effects of probiotics and commensals on intestinal epithelial physiology:implications for nutrient handling. *The Journal of physiology*,1:587(17):4169-74
39. Saleh, G. M. 2020. Isolation and characterization of unique fructophilic lactic acid bacteria from different flower sources. *Iraqi Journal of Agricultural Sciences*: 51(2):508-518
40. Scholz-Ahrens, K.E., P. Ade, B. Marten, P. Weber, W. Timm, Y. Açil, C.C. Glüer and J. Schrezenmeir, 2007. Prebiotics, probiotics, and synbiotics affect mineral absorption, bone mineral content, and bone structure. *J Nutr*, 137: 838S-846S
41. Seely, J. C. and P. K. Hildebrandt, 1990. Parathyroid gland. In: *Pathology of the Fischer Rat: Reference and Atlas* (Boorman GA, Eustis SL, Elwell MR, Montgomery CA, MacKenzie WF, eds). Academic Press, San Diego,pp: 537-543.
42. Seeman, E., and P. D. Delmas, 2006. Bone quality—the material and structural basis of bone strength and fragility. *New England journal of medicine*, 354(21), 2250-2261
43. Segawa, S., M. Fujiya, H. Konishi, N. Ueno, N. Kobayashi, T. Shigyo, and Y. Kohgo. 2011. Probiotic-derived polyphosphate enhances the epithelial barrier function and maintains intestinal homeostasis through integrin-P 38 MAPK pathway. *PLoS One*, 6, (8): (e23278).
44. Shapiro, F. 2016. Bone and Joint Deformity in Metabolic, Inflammatory, Neoplastic, Infectious, and Hematologic Disorders. In: *Pediatric Orthopedic Deformities*, Volume 1. Springer, Cham.pp: 411-504
45. Sherman, P.M., K.C. Johnson-Henry, H.P. Yeung, P.S.C. Ngo, J. Goulet, and T.A. Tompkins, 2005. Probiotics reduce enterohemorrhagic *Escherichia coli* O157:H7- and enteropathogenic *E. coli* O127:H6-induced changes in polarized T84 epithelial cell monolayers by reducing bacterial adhesion and cytoskeletal rearrangements. *Infect Immun*, 73: 5183-5188
46. Suvarna, V. and V. Boby, 2005. Probiotics in human health: A current assessment. *Current science*, 88(11), 1744-1748
47. Tizziani, T., R. F. M. O. Donzele, J. L. Donzele, A. D. Silva, J. C. L. Muniz, R. F. Jacob, G. Brumano and L. F. T. Albino, 2019. Reduction of calcium levels in rations

supplemented with vitamin D3 or 25-OH-D3 for broilers. *Revista Brasileira de Zootecnia* 48:e20180253

48. Vinderola G, C. Matar and G. Perdigon 2007. Milk fermentation products of *L. helveticus* R389 activate calcineurin as a signal to promote gut mucosal immunity. *BMC Immunology*, 8:19

49. World Health Organization and Food and Agricultural Organization of the United

Nations. 2001. Health and Nutritional Properties of Probiotics in Food Including Powder Milk with live Lactic Acid Bacteria. pp: 5-7

50. Yan, F. and D.B. Polk, 2002. Probiotic bacterium prevents cytokine-induced apoptosis in intestinal epithelial cells. *J Biol Chem*, 277 (52): (50959-50965).