

## MOLECULAR SEQUENCING AND PHYLOGENIC ANALYSIS TO VIRULENCE *nmuc-1* GENE IN VISCERAL LARVAE MIGRANCE

B. F. Hade<sup>1</sup>

Lecturer

<sup>1</sup>Dept. of Parasit, Coll. of Veter. Med., University of Baghdad.

[balkes.f@covm.uobaghdad.edu.iq](mailto:balkes.f@covm.uobaghdad.edu.iq)

### ABSTRACT

Toxocariasis is a zoonotic parasitic disease caused by *Toxocara canis* infected egg. Larval stage of this parasite has ability to migrate through intestinal wall and invade all body organs causing a visceral larvae migrant (VLM) syndrome. Diagnosis of VLM is problematic; there were no accurate laboratory test that reveals the presence of larvae infection in paratenic hosts (human, ruminants or poultry). The eggs were isolated from adult *T. canis* uteri and cultured in 0.2M H<sub>2</sub>S<sub>04</sub> solution for embryonation, mice were experimentally infected with embryonated eggs. Many histopathological changes detected in heart and kidney tissues of infected mice but it could not detected encysted larvae compared with molecular detection which confirmed infection within first three day post infection in tissue with accurate diagnosis for the first time in Iraq depend in detected virulence *nmuc-1* gene. Phylogenetic tree analyses mounted a low genetic variation (0.2) among Iraqi isolate and all other comparison isolates. In conclusion our result indicated that molecular method could diagnosis *T. canis* larvae infection in any meat or meat products of local or imported from inside or outside Iraq country and used as an accurate microbiological laboratory test used routinely in government laboratories.

**Keywords:** *Toxocara*, histopathology, heart and kidney tissues.

هادي

مجلة العلوم الزراعية العراقية -2020: 51: (3) 894-902

التسلسل الجزيئي وتحليل الشجرة التطوري لجين الضراوة *nmuc-1* المتسبب بمتلازمة هجرة اليرقات الحشوية

بلفيس فاضل هادي

مدرس

فرع الطفيليات اكلية الطب البيطري جامعة بغداد

المستخلص

داء السهميات مرض ناجم عن الإصابة ببيض طفيلي *Toxocara canis*. تتميز مرحلة الإصابة بالطور اليرقي لهذا الطفيلي بقدرته على الهجرة عبر جدار الأمعاء وغزو جميع أعضاء الجسم مسببة متلازمة اليرقات الحشوية المهاجرة (VLM)، لا يوجد تشخيص لهذه المتلازمة أو اختبار دقيق يكشف وجود يرقات الطفيلي في جسم المضيف (الإنسان أو المجترات أو الدواجن). تم عزل البيوض من رحم الطور البالغ للطفيلي *T. canis* وتنميتها بمحلول 0.2M H<sub>2</sub>S<sub>04</sub> لغرض الحصول على بيوض مخصبة وإصابة الفئران تجريبياً. تم تشخيص التغييرات النسيجية في عضوي القلب والكلى في أنسجة الفئران المصابة بالرغم من عدم إمكانية كشف الطور اليرقي للطفيلي مقارنة مع نتائج الفحص الجزيئي للانسجة باستخدام تفاعل البلمرة المتسلسل (PCR) الذي أكد التشخيص المبكر للطور اليرقي للطفيلي اعتماداً على تضخيم جين *nmuc-1* وخلال أول ثلاثة أيام بعد الإصابة، لأول مرة في العراق. أكدت نتائج شجرة التطور بوجود تباين جيني منخفض (0.2) بين العزلة العراقية وجميع عزلات المقارنة الأخرى، كما وأشارت النتائج إلى أن التشخيص الجزيئي يمكن أن يكشف عن وجود عدوى اليرقات *T. canis* في عينات اللحوم أو منتجات اللحوم المحلية أو المستوردة من خارج العراق واستخدامه كاختبار دقيق يستخدم بشكل روتيني في مختبرات المستشفيات الحكومية.

كلمات مفتاحية: *Toxocara*، التشريح المرضي، أنسجة القلب و الكليتين.

\*Received:17/9/2019, Accepted:24/12/2019

## INTRODUCTION

*Toxocara canis* remains a problem throughout the world because it causing multisystem zoonotic disease in the paratenic hosts such as humans, ruminants, poultry, rabbit and rodents (8). Human infection occurred accidental by the ingested contaminated soil, food, water or unwashed vegetables with *T. canis* embryonated eggs which lay on dog feces (dirt); as well as through ingestion of *T. canis* encysted larvae present in undercooked ruminants or poultry liver or meat as a paratenic hosts (26, 21 and 1), leading to many complications due to the migration of *T. canis* larvae to all body organs and invade tissue like liver, lungs or the nervous system (5, 19 and 16). Stool examination for *T. canis* eggs and larvae not useful because larvae not matured in paratenic host like human and rabbit (17 and 15). Infective larvae (L2) have ability to produce *Toxocara* Excretory/Secretory proteins such as (MUC-120) that help it to penetrate host intestinal wall then invade and migrate to widely various tissues including the liver, lung (10) musculature and CNS, remain on arrested stage without development to adult stage while most infections are asymptomatic but manifests in humans causing the well-characterized syndrome of, ocular larva migrans (OLM), visceral larva migrans (VLM), neurotoxocariasis (NT) and/or covert toxocariasis (CT) (19). The protein MUC-120 expressed by *nmuc-1* gene, surface coat glycoprotein protein (29). *T. canis* larvae could invade host immune system by surface coat protein MUC-120 which is released in response to binding by host antibody molecules or effector cells (31). Positive seroprevalence rate of Toxocariasis in Iraq recorded (27.27%) at child age and (23.33%) in adult people (9). Some degree of antibody cross-reactivity between *T. canis* Excretory/Secretory antigens and proteins excreted by other nematodes lead to false positive results, such as *Trichuris trichiura* (4), *Ascars suum* (6) and hookworm (25). A modern laboratory assay should be used to provide an accurate diagnosis of Toxocarais (VLM) infection since no accurate laboratory test that reveals the presence of larvae infection in all paratenic hosts.

## MATERIALS AND METHODS

**Parasites Samples Collection:** Thirty two *T. canis* adult worms were obtained from puppies stool naturally infected with *T. canis* after treatment with albendazole. The unembryonated egg isolated from females uterus to 0.2M H<sub>2</sub>SO<sub>4</sub> solution for embryonation, An experimental infection which involved two mice groups; The first included 12 mice experimentally infected with 1500 embryonated eggs, and the second, control group, 3 mice inoculated distal water. Mice were killed at 2, 7, 11, 18, 24 and 32 day post infection (DPI), two mice each day, small portions from heart and kidney tissues collected in 0.4% HCl for up to 12 h at 37°C, about 3 ml of the sediment were centrifuged for 5 min at 2500 rpm and washed with distilled water to remove acid and stored in -4°C until required for DNA extraction

### Histopathological Examinations

Small portion from heart and kidney tissues of infected mice with *T. canis* embryonated eggs transferred to 10% formalin solution 24 h for stained with Hematoxyline and Eosin stain (18).

### Genomic DNA isolation protocol

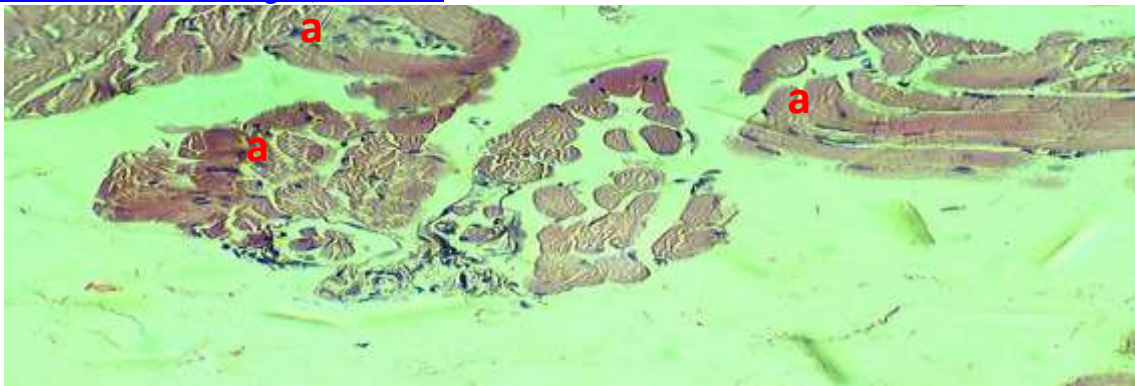
Total genomic DNA were extracted from Heart and kidney tissue by grinded for 3 min using a mechanical grinder and was subsequently purified using the commercially available DNA mini Kit (Promega, USA) according to the manufacturer's instructions. DNA concentration and purity were determined by using Nano Drop (Thermo scientific).

### Amplification of *T. canis* larvae DNA by conventional PCR

Conventional Polymerase Chain Reaction (PCR) was performed on all DNA samples to amplify a fragment of *nmuc-1* gene by the designed new specific oligonucleotide primer pair FR5'-TCTGCGTTGCTACACCACAA-3' and RE5'-AAGTTTGCACAGTCGTTGGC-3' for each one using purified larvae DNA as a template. PCR final reaction volume 20µL was performed including Master Mix (Bioneer, Korea); 10 pmol of each primer with 1 µL, 3 µL template DNA and 15µL Nuclease-free water. The temperature profile was one cycle of 94° C for 5min (primary denaturation), followed by 40 cycles of 94° C for 30sec

(denaturation), 58°C for 40sec (annealing), and 72°C for 30sec (extension), and a final extension 72°C for 5 min. A sample containing water instead of template DNA was included in each run as a negative control. PCR products were analyzed by electrophoresis on a 1.2% agarose gel and photographed under an ultraviolet transilluminator (20).=

**Phylogenetic analyses:** forward and reverse sequences from each PCR product were assembled using AccuPrep<sup>w</sup> PCR purification Kit (INTRON). Phylogenetic tree carried out employing (Mega 6) Neighbour Joining method to find out phylogenetic relationship with other sequences deposited in NCBI (<http://www.ncbi.nlm.nih.gov/GenBank>).



**Figure 1. Histopathological section in heart tissue of infected mice, showed (a) moderate infiltration of mononuclear cells. (H and E stain, 20X).**

Other section in heart tissue showed the vasculature between bundles of cardiac tissue appeared peri and intra infiltration of

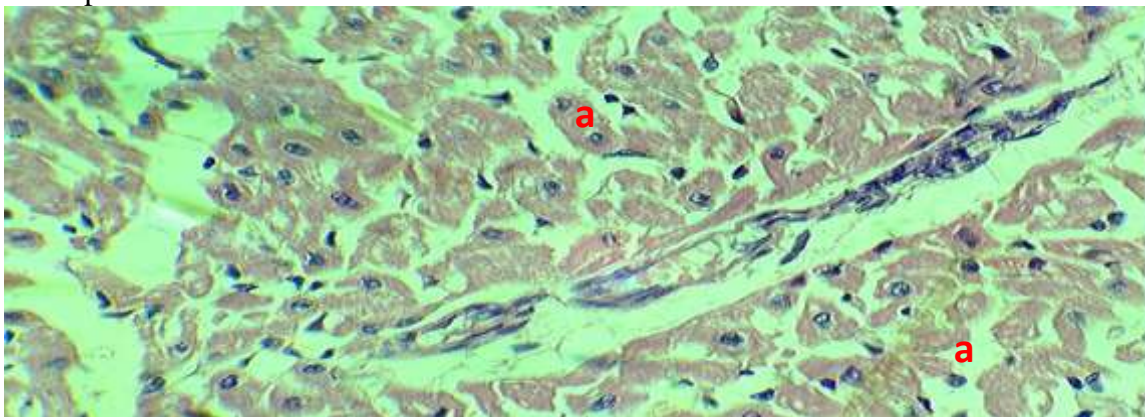
## RESULTS AND DISCUSSION

### Histopathological Changes in Heart and Kidney Tissues:

#### Microscopic Appearance of Heart Tissue in Infected Mice

The infections appeared earlier on infected mice with *T. canis* embryonated eggs, histological changes observed in heart tissue of infected mice characterized by inflammatory reactions were the heart section showed moderate infiltration of mononuclear cells mainly lymphocyte and macrophage filtration between cardiac muscles as clarified in figure 1.

mononuclear cells mainly the macrophages as clarified in figure 2.

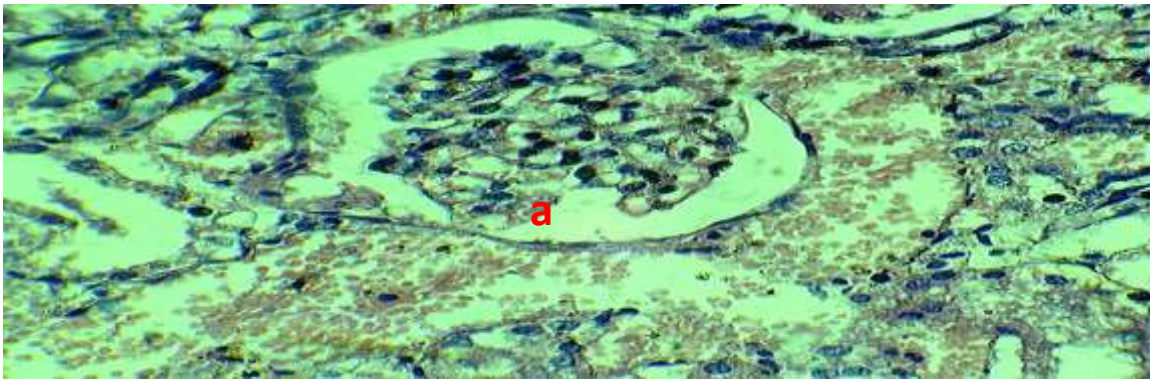


**Figure 2. Histopathological section in heart tissue of infected mice, showed vasculature between bundles of cardiac tissue appeared peri and (a) intra infiltration of MNCs. (H and E stain, 40X).**

#### Microscopic appearance of kidney tissues in infected Mice

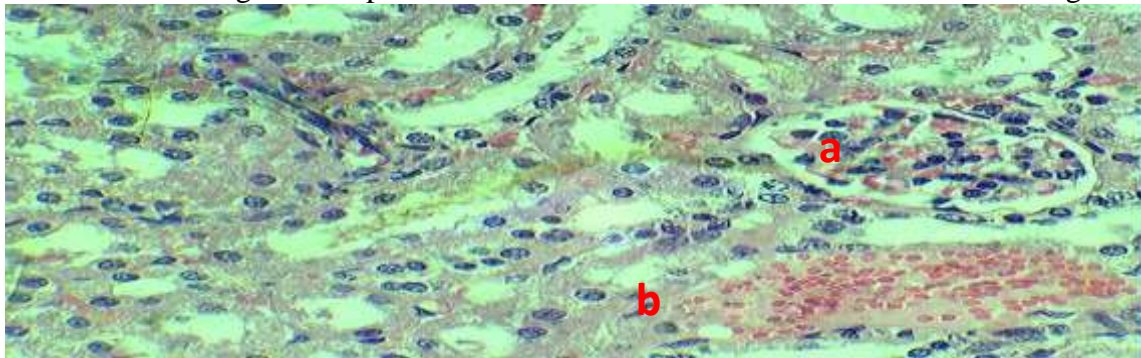
The lesion of renal tissue which infected with embryonated *T. canis* eggs investigated moderate pathological lesion characterized by

glomerular endothelial degeneration (vacuolar degeneration) with few infiltration of mononuclear cells (mononuclear, lymphocyte and macrophage cells), as demonstrated in figure 3



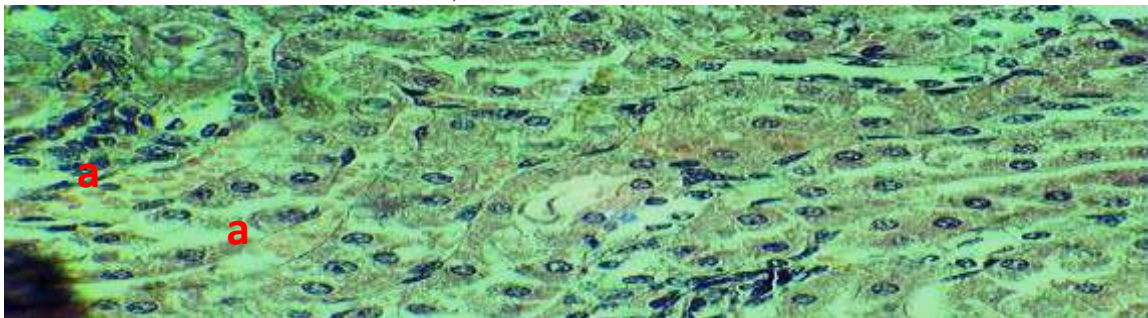
**Figure 3. Histopathological section in Kidney tissue of infected mice showed (a) moderate renal tubules degenerative changes (H and E stain, 40X).**

The infection also demonstrated enlarged glomeruli due to congested capillaries and infiltrated with MNCs also congestion of the renal blood vessels as clarified in figure 4.



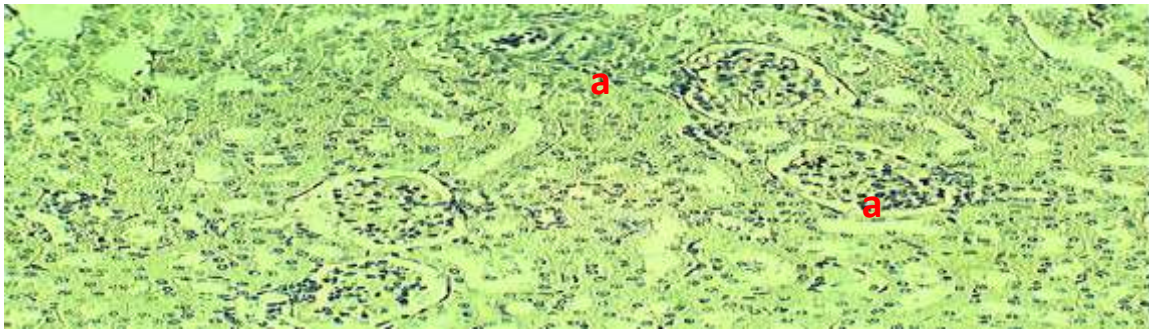
**Figure 4. Histopathological section in Kidney tissue of infected mice showed (a) enlarged glomeruli and (b) congestion of the renal B.Vs. (H and E stain, 40X).**

Collecting tubules in medulla of kidney with severe degenerative changes of proximal tubules and some of them necrotized, focal MNCs infiltrated the peritubular tissues as demonstrated in figure 5.



**Figure 5. Histopathological section in Kidney tissue of infected mice clarified (a) collecting tubules in medulla of kidney (H and E stain, 40X).**

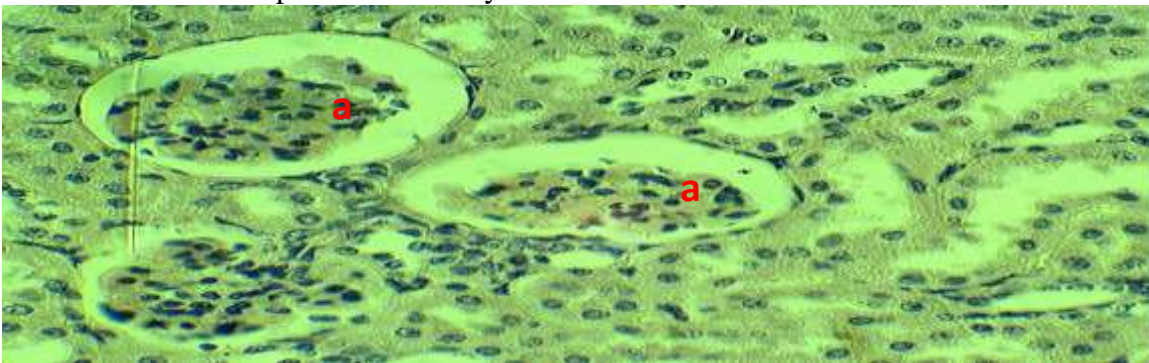
Enlargement of glomerular tuft with decreased bowman's spaces, and severe congestion of other glomerular capillary tuft and contained eosinophilic material, the renal tubular epithelium degenerated as showed in figure 6



**Figure 6. Histopathological section in Kidney tissue of infected mice clarified (a) renal tubular epithelium degenerated (H and E stain, 20X).**

Other section of infected kidney tissue demonstrated renal glomeruli shrinkage due to high cellular immune response caused by *T.*

*canis* larvae migration within kidney tissues as showed in figure 7.



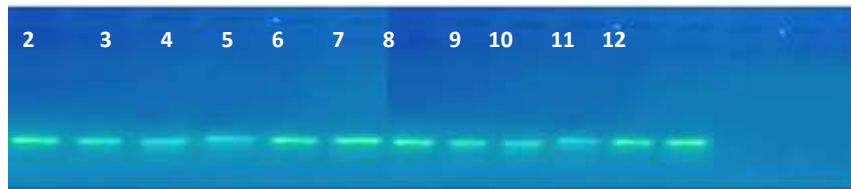
**Figure 7. Histopathological section in Kidney tissue of infected mice clarified (a) renal glomeruli shrinkage (H and E stain, 40X).**

The presence of inflammatory reactions of mononuclear cells mainly lymphocyte and macrophage in heart and kidney tissues of infected mice with *T. canis* embryonated eggs was an indication of the moderate to high cellular immune response agents *T. canis* larvae antigens and that deal with Strube *et al.* (28) findings that described a high inflammatory reactions with typical epithelioid granulomata formation around *T. canis* larvae which more frequently occurred in the livers of rats, chickens, guinea pigs at 10 days PI, and in rabbit liver and lung tissues infected with *T. canis* embryonated eggs, likely reflect more effective adaptive immune responses against larval antigens in these species (10). Present study indicated that experimented infected mice suffer from VLM syndrome in heart and kidney tissues with serious complications compared with normal heart and kidney tissue in control group and that deal with (13) results which indicated that clinical spectrum of cardiac involvement in *Toxocara* infections includes myocarditis. While multiple renal glomeruli lesions with presence

of eosinophilic accumulation in kidney tissue clarified in this study differ from (2) results that enable detection the migrating of *Toxocara* larvae in kidney tissues. *T. canis* larvae were not found in heart and kidney tissues of infected mice in this study, this deal with other study results and may be due to the larvae continuously migrate (24), or their low bioavailability in these tissues, moreover *T. canis* larvae has been proven to possess efficient strategies to escape the immune attack because larva has ability to coat itself with MUC-120 protein and hide from host immune system (21).

## 2) Molecular Detection to *T. canis* in Heart and Kidney tissues:

Genomic DNA were extracted from heart and kidney tissue successfully, DNA concentration was measured between 34.3-112.2 ng/μl and the purity of DNA ranged between 1.5-1.74 as shown in figure 8. Our results give high *T. canis* larvae DNA concentration compared with (3 and 12) results with 14 ng of *T. canis* larvae DNA.

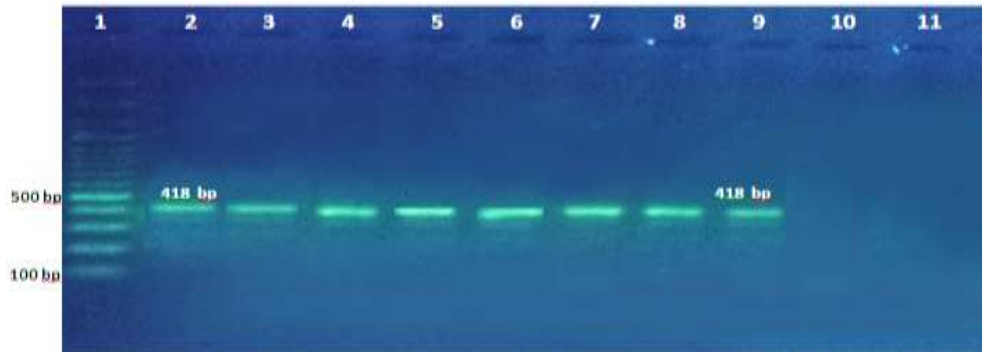


**Figure 8. Genomic DNA for all samples (Voltage 60, Gel conce. 0.8%, Time: 1 h).**

**Molecular identification of virulence larvae *nmuc-1* gene**

Molecular Identification of *T. canis* larvae based on amplify partial region of virulence gene *nmuc-1*. Our results indicated that two DNA samples extracted from heart tissue and

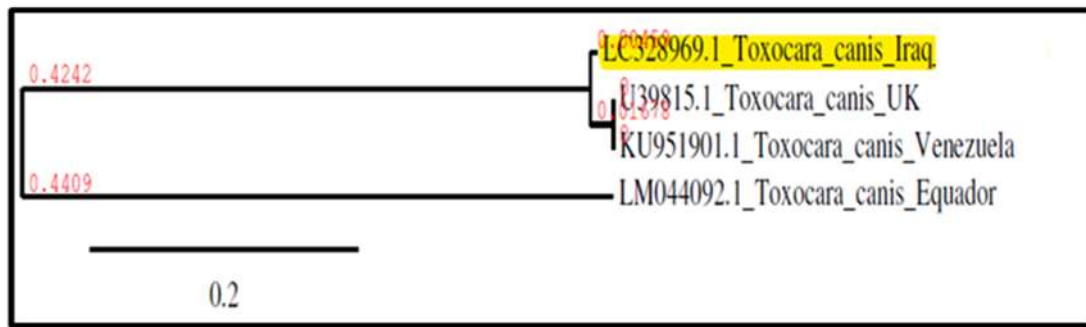
all DNA sample extracted from kidney tissues were belong to *nmuc-1* gene of *T. canis* larvae stage, figure 9



**Figure 9. Line 1: Molecular Marker (100bp); lines (2, 3) DNA of *T. canis* larvae extracted from heart tissue of infected mice; line (4-9) DNA of *T. canis* larvae extracted from kidney tissue of infected mice; line (10, 11) negative control (Volt.60, Gel concentration: 1.2% agarose, Time: 1.5 hrs).**

The seropositive rate for human toxocarosis was high in Iraq (9). *T. canis* larvae was the most virulence parasitic pathogen which caused visceral, ocular, nervous, cutaneous or covert larva migrans, however, if embryonated eggs or larvae accidentally infected humans, the larvae migrate to the liver, lungs, eyes, or brain, but cannot reach the intestine (27). Larval stage of *T. canis* could release significant amounts of Excretory and Secretory antigens *in vivo* and under *in vitro* culture conditions and the major mucin protein encode by virulence *nmuc-1* gene (23). The presence of *T. canis* larval MUC-120 (mucin) protein highlights the ability of this parasite to resist an attack of the host cellular immune system, allowing survival in host tissues for many years, since the major function of mucin protein was formation of larval surface coat which necessary for larvae invasion and protect from antibody and

eosinophil attack during its migration through all body organs tissue (11). Our result is the first study in Iraq that detective *T. canis* larval stage in heart and kidney tissues using virulence *nmuc-1* gene, since it was the only way to detection *T. canis* larvae stage infection in tissue, and confirmed that *T. canis* eggs were hatched on stomach and larvae stage (L2) migrated and recovery at infected mice tissues on first third day post infection. PCR product was sequenced deposited in NCBI with accession numbers LC328969 and at DDBJ and ENA database for the first time in Iraq. Phylogenetic analyses carried out employing (mega 6), depend on Fixation index ( $F_{ST}$ ), mounted a low genetic variation (0.2) among all comparison isolates and that means minimal genetic diversity among them and that populations are genetically identical as shown in figure 10.



**Figure 10. Phylogenetic relationship of aligned sequences of *T. canis* larvae stage**

Depending on genetic distance with in phylogenetic tree for aligned sequence Iraqi isolate recoded (0.00459) which is more closely to Venezuela and United Kingdom isolates (KU951901 and U39815, respectively) aligned sequence which splits from the same node and recorded (0.01618), than Ecuador isolate (LM044092) which mounted (0.4409). The result of present study depending on phylogenetic tree analysis indicated that Iraqi *nmuc-1* gene empty from any mutation. The research was able to create simple molecular diagnostic equipment (kit) depending on detection *nmuc-1* virulence gene specific designed primer and PCR technique that enables scientific laboratories in government hospitals to used it for detect and diagnose the infection with *T. canis* parasite (larvae stage) in the patient tissues like human, ruminant and poultry which provides accurate, rapid and inexpensive diagnosis, thus preventing the spread of infection by detecting contaminated meat or products and prevent removed organs surgically. Although a number of scientists used molecular techniques to estimate the genetic parameter and demonstrate evaluate the genetic effects (22 and 30), PCR technique followed by phylogenetic tree analysis perfect molecular methods for detection and identification of genetic variants of parasites which agree with Faraj *et al.*, (7). *nmuc-1* gene was virulence gene and can be used as molecular marker to detected VLM syndrome in paratenic host, including human. This study results recommended depend on this gene to ensure if there was an infection with *T. canis* larval stage in tissue of sheep, poultry or cattle local or imported meat or meat products from inside or outside Iraq country and used it for the first time in Iraqi standardization and quality control laboratories as an accurate

microbiological laboratory test used routinely in government hospitals.

#### REFERENCES

1. Ahn, S. J., S. J. Woo, Y. Jin, Y. S. Chang, T. W. Kim, J. Ahn, J. W. Heo, H. G. Yu, H. Chung and K. H. Park. 2014. Clinical features and course of ocular toxocariasis in adults. *PLoS neglected tropical diseases*, 8, e2938
2. Almatary, A. and H. Bakir. 2016. Human case of visceral larva migrans syndrome: pulmonary and hepatic involvement. *Helminthologia* 53(4): 372-377
3. Borecka, A., J. Gawor, M. Niedworok and B. Sordyl. 2008. Detection of *Toxocara canis* larvae by PCR in the liver of experimentally infected mongolian gerbils (*Meriones unguiculatus*). *Helminthologia*, 45, 147
4. Cancrini, G., A. Bartoloni, E. Zaffaroni, P. Guglielmetti, H. Gamboa, A. Nicoletti, and C. Genchi. 1998. Seroprevalence of *Toxocara canis*-IgG antibodies in two rural Bolivian communities. *Parassitologia*, 40(4)December, 473-475
5. Despommier, D. 2003. Toxocariasis: clinical aspects, epidemiology, medical ecology, and molecular aspects. *Clinical microbiology reviews*, 16, 265-272
6. Elefant, G. R., S. H. Shimizu, M. C. Arroyo, C. M. A. Jacob and A. W. Ferreira. 2006. A serological follow-up of toxocariasis patients after chemotherapy based on the detection of IgG, IgA, and IgE antibodies by enzyme-linked immunosorbent assay. *Journal of clinical laboratory analysis*, 20, 164-172
7. Faraj, A. A., B. F. Hade and A. M. Al-Amery. 2019. Conventional and molecular study of *Babesia* spp. natural infection in dragging horses at some areas of Baghdad city, Iraq. *Iraqi Journal of Agricultural Sciences*:50(3):909- 915
8. Gasser, R. B., P. K. Korhonen, X. O. Zhu and N. D. Young. 2016. Harnessing the

*Toxocara* genome to underpin toxocariasis research and new interventions. Advances in parasitology. Elsevier

9. Hadi, A. M. 2017. An ELISA Serodiagnostic survey of *Toxocara canis* in normal and hospitalized eye patients from Baghdad, Iraq." Online Journal of Veterinary Research, 21, 45-50

10. Hade, B. F, A. M. Al-Amery, Z. Ibrahim and S. Saadedin. 2018. Histopathological Study of Different VLM Stages *Toxocara canis* Infection in Liver of Rabbits\Iraqi Journal of Biotechnology, 17(2): 47-56.

11. Hade, B. F, S. Saadedin and A. M. Al-Amery. 2018. Sequencing and phylogenic variation of ITS-2 region and *rrnL* gene in *Toxocara canis* of Iraqi isolation. Journal of Biodiversity and Environmental Sciences, 13 (1) : 71-82.

12. Hade, B. F, A. M. Ghareeb and M. H. Kawan. 2015. Direct Amplification of B1 gene of *Toxoplasma gondii* DNA using nested polymerase chain reaction following microwave treatment for whole blood samples\The Iraqi Journal of Veterinary Medicine,39(1): 23 -27.

13. Kong, J., J. Won, J. Yoon, U. Lee, J. I. Kim and S. Huh. 2016. Draft Genome of *Toxocara canis*, a Pathogen Responsible for Visceral Larva Migrans. The Korean Journal of parasitology, 54, 751

14. Kuenzli, E., M. Neumayr, M. Chaney and J. Blum. 2016. "Toxocariasis-associated cardiac diseases—a systematic review of the literature." Acta tropica 154: 107-120

15. Lee, R. M., M. E. Moore, M. Bottazzi and P. J. Hotez. 2014. "Toxocariasis in North America: a systematic review." PLoS neglected tropical diseases 8(8): e3116

16. Lee, J. Y., M. H. Yang, J. H. Hwang, M. Kang, J. W. Paeng, S. Yune, B. J. Lee and D. C. Choi. 2015. The prevalence of toxocariasis and diagnostic value of serologic tests in asymptomatic Korean adults. Allergy, asthma & immunology research, 7, 467-475

17. Liao, C. W., P. Sukati, C. M. D'lamini, Y. H. Chou, Y. C. Liu, M. H. Huang, J. Chung, J. Mtsetfwa, J. Jonato and W. T. Chiu. 2010. "Seroprevalence of *Toxocara canis* infection among children in Swaziland, southern Africa." Annals of Tropical Medicine & Parasitology 104(1): 73-80

18. Luna, L. G. 1968. Manual of histologic methods of the armed forces institute of pathology, McGraw-Hill, 26 (51): 78-84

19. Macpherson, C. N. 2013. The epidemiology and public health importance of toxocariasis: a zoonosis of global importance. International journal for parasitology, 43, 999-1008

20. Maniatis, T., E. F. Fritsch and J. Sambrook. 1982. Molecular cloning: a laboratory manual, Cold Spring harbor laboratory Cold Spring Harbor, NY8(8): 311-16

21. Maizels, R. M. 2013. *Toxocara canis*: molecular basis of immune recognition and evasion. Veterinary parasitology, 193, 365-374

22. Mahmood S. KH. A. A. Mhawesh T. S. Abdullah. 2019. Comet Assay for Rapid Detection of DNA Base Damage in Plants. , Iraqi Journal of Agricultural Sciences: 50(1):495-499

23. Moreira, G. M., T. Delima, M. Mendonca, A. N. Moreira, Â. J. A. McBride, C. J. Scaini and F. R. Conceicao. 2014. Human toxocariasis: current advances in diagnostics, treatment, and interventions. Trends in Parasitology, 30, 456-464

24. Othman, A. A. 2012. "Therapeutic battle against larval toxocariasis: are we still far behind?" Acta tropica 124(3): 171-178

25. Rubinsky-Elefant, G., M. Dasilva-nunes, R. S. Malafronte, P. T. Muniz and A. M. U. Ferreira. 2008. Human toxocariasis in rural Brazilian Amazonia: seroprevalence, risk factors, and spatial distribution. The American Journal of Tropical Medicine and Hygiene, 79, 93-98

26. Rubinsky-Elefant, G., C. E. Hirata, J. H. Yamamoto and M. U. Ferreira. 2010. Human toxocariasis: diagnosis, worldwide seroprevalences and clinical expression of the systemic and ocular forms. Annals of Tropical Medicine and Parasitology, 104, 3-23

27. Santarém, V. A., B. E. L. Chesine, G. Lamers, P.A.F. Rubinsky-Elefant and F. Giuffrida. 2011. Anti-*Toxocara* spp. antibodies in sheep from southeastern Brazil. Veterinary Parasitology 179(1-3): 283-286

28. Strube, C., L. Heuer and E. Janecek. 2013. *Toxocara* spp. infections in paratenic hosts. Veterinary parasitology 193(4): 375-389



29. Theodoropoulos, G., S. J. Hicks, A. P. Corfield, B. G. Miller and S. D. Carrington. 2001. The role of mucins in host–parasite interactions: Part II–helminth parasites. *Trends in parasitology*, 17, 130-135
30. Wuhaib, K. M., B. H. Hadi and W.A.Hassan.2018. Genotypic and Phenotypic Correlation in Maize and Path Coefficient I-Agronomic Traits, , Iraqi Journal of Agricultural Sciences: 49(2):179-187
31. Zhu, X. Q., P. K. Korhonen, H. Cai, N. D. Young, P. Nejsun, G. Vonsamson, P. R. Boag, P. L. Tan, Q. Li. and J. Min. 2015. Genetic blueprint of the zoonotic pathogen *Toxocara canis*. *Nature communications*, 6, 6145.